

Case Report

Disseminated Cryptococcal Disease with Skeletal and Pulmonary Involvement

¹Nikko Rowe Asuncion Tabliago, ²Paula McKenzie, ³Caroline Dillon and ⁴Amelia Morgan

¹Department of Internal Medicine, Geisinger Medical Center, USA

²Department of Infectious Diseases, Geisinger Medical Center, USA

³Department of Pharmacy, Geisinger Medical Center, USA

⁴Department of Internal Medicine-Pediatrics, Geisinger Medical Center, USA

Article history

Received: 13-03-2022

Revised: 08-06-2022

Accepted: 01-07-2022

Corresponding Author:

Nikko Rowe Asuncion

Tabliago

Department of Internal
Medicine, Geisinger Medical
Center, USA

Email: nikko.tabliago@gmail.com

Abstract: *Cryptococcus neoformans* is an encapsulated yeast that typically causes illness in immunocompromised hosts. Manifestations of the disease include pulmonary, Central Nervous System (CNS), and rare skeletal involvement. Optimal antifungal therapy for skeletal involvement has yet to be established. Here we present a potential antifungal regimen for disseminated cryptococcal disease with skeletal and pulmonary involvement in a patient with Chronic Lymphocytic Leukemia (CLL) on ibrutinib therapy.

Keywords: Cryptococcosis, Osteomyelitis, Fluconazole, Disseminated

Introduction

Ibrutinib is a Bruton Tyrosine Kinase (BTK) inhibitor approved in 2014 to treat Chronic Lymphocytic Leukemia (CLL). Since its inception, it has shown considerable improvements in CLL's progression-free survival and overall survival in addition to improvement in hematologic variables (Burger *et al.*, 2015). While it has garnered acclaim for its usefulness in lymphoproliferative disease, it has also gathered notoriety due to an alarming amount of reports of Invasive Fungal Infections (IFIs) after starting ibrutinib. Chamilos *et al.* (2018) reported 41 cases of IFI including cryptococcosis, invasive aspergillosis, and mucormycosis in patients on ibrutinib therapy (Chamilos *et al.*, 2018). It has been reported that the median time from the start of ibrutinib treatment until the first symptoms of IFI was 45.5 days (range 1-540 days) (Ruchlemer *et al.*, 2019). Early occurrences of IFI are thought to be due to the inactivation of monocytes allowing increased susceptibility in patients who were previously colonized to these typically non-pathogenic fungi (Grommes and Younes, 2017). Cryptococcosis, specifically *Cryptococcus neoformans*, has historically been an ailment in immunocompromised hosts. Cryptococci reside in diverse ecological niches and are typically isolated to soil microorganism interaction with vertebrates possibly aiding in its spread (May *et al.*, 2016). As the portal of entry is the lungs, pneumonia is the presenting diagnosis, but it can manifest elsewhere in the body. In 2013, only 89 cases of cryptococcosis were reported to involve bones and joints. Characteristic

symptoms of skeletal cryptococcosis are pain and swelling at the site. Amongst implicated bones, the majority involve the vertebrae, skull, and femur. The ribs and ilium comprised 8.1 and 4.9% of affected sites, respectively (Zhou *et al.*, 2015). This is different from previously reported most common sites as the pelvis and rib in 1977 (Chleboun and Nade, 1977). One patient had CLL; he presented with a lump on his scalp and was found to have a cryptococcal skull granuloma (Galloway and Schochet, 1981). A similar case of disseminated cryptococcosis in a patient with CLL on ibrutinib did not have any skeletal involvement (Okamoto *et al.*, 2016). To the best of our knowledge, this case is the first reported case of disseminated cryptococcosis with skeletal and pulmonary involvement in an individual with CLL who was on ibrutinib therapy.

Objective

While guidelines for cryptococcal meningitis have been outlined in detail by the infectious diseases society of America, optimal therapy for skeletal cryptococcosis has yet to be established. Below, we present a case of skeletal cryptococcosis and a possible antifungal regimen.

Case Report

A 77-year-old female with CLL on ibrutinib presented with a one-week history of dyspnea, fatigue, and fevers and a reported Tmax of 105.5°F (40.8°C). She was diagnosed with pneumonia and given a seven-day course of levofloxacin. Her fevers reoccurred along with new orthopnea and worsening lower extremity edema. She

was tachycardic, tachypneic, and hypoxic requiring two liters of oxygen. Initial laboratory studies showed a white blood cell count of 19,520 cells/uL, hemoglobin 7.6 g/dL, platelets 84,000 cells/uL and elevated transaminases. She was started on ceftriaxone and azithromycin but remained febrile. Ibrutinib was discontinued at this time as well due to her acute infection. Diuresis subjectively improved her orthopnea, dyspnea, and peripheral edema, but her fevers continued to spike up to 102.2°F (39.0°C); antibiotic coverage was broadened to cefepime to provide (SPICE) *Serratia*, *Pseudomonas*, indole-positive *Proteus*, *Citrobacter*, and *Enterobacter* organism coverage. Our differential expanded to include evaluation for reactivation of *Epstein-Barr Virus* (EBV), *Cytomegalovirus* (CMV), and *Cryptococcus* gave her immunocompromised status from taking daily ibrutinib. EBV and CMV returned negative. Serum Cryptococcal antigen titer was 1:160. Blood cultures grew *Cryptococcus neoformans*. A working diagnosis of disseminated cryptococcal infection was established and a lumbar puncture was performed to rule out Central Nervous System (CNS) involvement. Cerebrospinal Fluid (CSF) studies did not show any findings consistent with fungal meningitis and culture growth was ultimately negative. Transthoracic Echocardiogram (TTE) showed a 1.2 × 0.78 cm vegetation with moderate mitral regurgitation. Transesophageal Echocardiogram (TEE) showed that this lesion was more consistent with mitral valve chordae calcification. She received two weeks of induction antifungal therapy with IV amphotericin B and oral flucytosine. At the time of discharge, her oral consolidation regimen consisted of fluconazole 400 mg for eight weeks with short interval follow-up imaging regarding possible cardiac mass. Outpatient cardiac Magnetic Resonance Imaging (MRI) was completed in addition to a Positron Emission Tomography (PET) scan and it was determined the vegetation was likely a myxoma, not fungal endocarditis. Based on the site of the lesion and the overall stability of the patient on the current regimen, the decision was made to not pursue an invasive biopsy of this lesion as it would not have changed the current management. Of particular interest in this imaging was the newly identified active osteolytic lesions (Fig. 1 and 2) scattered throughout her skeleton thought to be concerning for CLL disease progression. The decision was made to biopsy the more accessible 4th rib lesion which ultimately showed small B-cell lymphoma compatible with CLL as well as necrotizing granulomatous inflammation with fungal elements, morphologically compatible with *Cryptococcus* (Fig. 3). After this result, the regimen was changed to oral fluconazole 800 mg daily and oral flucytosine 1,250 mg twice daily for two weeks for re-induction, then transitioned to fluconazole 400 mg daily for 8-10 weeks and then lifelong fluconazole 200 mg daily.

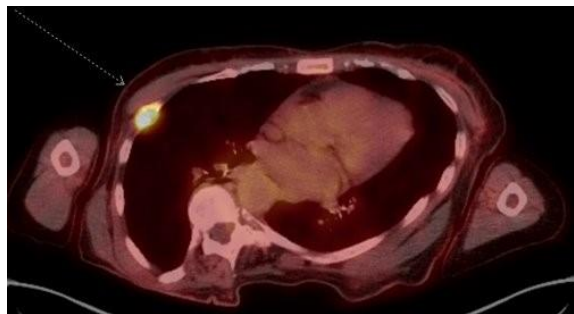


Fig. 1: Right chest, PET image. The metabolically active osteolytic lesion demonstrated in the right 4th rib thought to be consistent with CLL progression

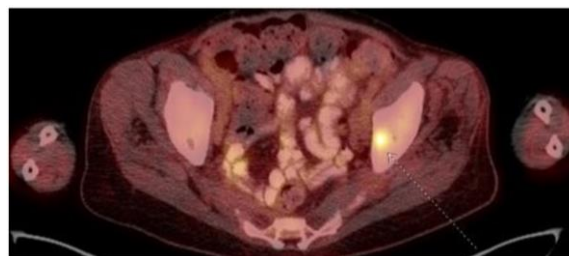

Fig. 2: Left ilium, PET image. The metabolically active osteolytic lesion demonstrated in the left iliac bone thought to be consistent with CLL progression

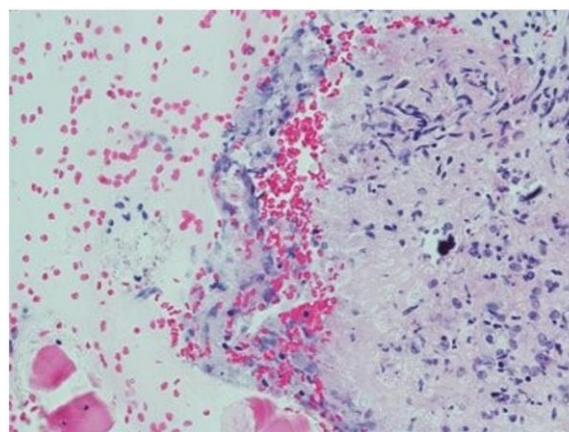


Fig. 3: Hematoxylin and Eosin (H and E) stain of a section of core needle biopsy of rib lesion (objective x40)

Discussion

To our knowledge, this case is the first reported case of disseminated cryptococcosis with skeletal and pulmonary involvement in an individual with CLL who was on ibrutinib therapy. It is likely that the *Cryptococcus* spp. First manifested as pneumonia and then spread via hematogenous dissemination to involve the bony structures. A literature review of disseminated skeletal cryptococcosis showed no significant differences in mortality rates amongst four treatment regimens: Medical

monotherapy, combined medical therapy, medical monotherapy with surgery, and combined medical therapy with surgery (Zhou *et al.*, 2015); this may be skewed due to the small sample size (n = 40). It is reasonable that the combination of surgery for source control and combined medical therapy would be a plausible regimen to ensure clearance of infection. As our patient potentially had multiple bony sites affected, surgical debridement would be difficult to safely pursue. Fluconazole concentration may only reach 33% in bone (Ashbee *et al.*, 2014). Current recommendations neither support nor refute routine Therapeutic Drug Monitoring (TDM) for fluconazole. There is limited data available on the bone concentrations of flucytosine in humans and animals. Polak (1979) reported that flucytosine concentration reached up to 30% in bone. It is recommended that TDM should be performed in the majority of patients receiving flucytosine with lower target concentrations of >20-40 mg/L (Ashbee *et al.*, 2014).

Conclusion

There is little consensus as to a definitive antifungal regimen. We have presented a potential antifungal regimen for disseminated cryptococcal disease with skeletal and pulmonary involvement. Its efficacy in successfully suppressing this challenging infection will warrant close monitoring.

Acknowledgment

Xiaoyu Tang, MD-Pathology, Geisinger Medical Center, Danville, Pennsylvania, United States of America.

Author's Contributions

Nikko Rowe Asuncion Tabliago: Manuscript write, literature review and edited.

Paula McKenzie: Manuscript review and edited, supervision of project.

Caroline Dillon: Manuscript review and edited.

Amelia Morgan: Manuscript write and edited.

Ethics

This article is original and contains unpublished material. The authors declare no ethical issues. Informed consent was acquired from the patient.

References

Ashbee, H. R., Barnes, R. A., Johnson, E. M., Richardson, M. D., Gorton, R., & Hope, W. W. (2014). Therapeutic Drug Monitoring (TDM) of antifungal agents: Guidelines from the British Society for Medical Mycology. *Journal of Antimicrobial Chemotherapy*, 1162-1176. doi.org/10.1093/jac/dkt508

Burger, J. A., Tedeschi, A., Barr, P. M., Robak, T., Owen, C., Ghia, P., ... & Kipps, T. J. (2015). Ibrutinib as initial therapy for patients with chronic lymphocytic leukemia. *New England Journal of Medicine*, 373(25), 2425-2437. doi.org/10.1056/NEJMoa1509388

Chamilos, G., Lionakis, M. S., & Kontoyiannis, D. P. (2018). Call for action: Invasive fungal infections associated with ibrutinib and other small molecule kinase inhibitors targeting immune signaling pathways. *Clinical Infection Diseases*, 66(1), 140-148. doi.org/10.1093/cid/cix687

Chleboun, J. O. H. N., & Nade, S. Y. D. N. E. Y. (1977). Skeletal cryptococcosis. *The Journal of Bone and Joint Surgery. American Volume*, 59(4), 509-514. doi.org/10.2106/00004623-197759040-00016

Galloway, D. C., & Schochet, S. S. (1981). Cryptococcal skull granuloma: Case report. *Journal of Neurosurgery*, 54(5), 690-692. doi.org/10.3171/jns.1981.54.5.0690

Grommes, C., & Younes, A. (2017). Ibrutinib in PCNSL: The Curious Cases of Clinical Responses and Aspergillosis. *Cancer Cell*, 31(6), 731-733. doi.org/10.1016/j.ccell.2017.05.004

May, R. C., Stone, N. R., Wiesner, D. L., Bicanic, T., & Nielsen, K. (2016). *Cryptococcus*: From environmental saprophyte to the global pathogen. *Nature Reviews Microbiol*, 14(2), 106-117. doi.org/10.1038/nrmicro.2015.6

Okamoto, K., Proia, L. A., & Demarais, P. L. (2016). Disseminated cryptococcal disease in a patient with chronic lymphocytic leukemia on ibrutinib. *Case Reports in Infectious Diseases*, 2016. doi.org/10.1155/2016/4642831

Polak, A. (1979). Pharmacokinetics of amphotericin B and flucytosine. *yPostgrad Medical Journal*, 55(647), 667-670. doi.org/10.1136/pgmj.55.647.667

Ruchlemer, R., Ben-Ami, R., Bar-Meir, M., Brown, J. R., Malphettes, M., Mous, R., ... & Lachish, T. (2019). Ibrutinib-associated invasive fungal diseases in patients with chronic lymphocytic leukemia and non-Hodgkin lymphoma: an observational study. *Mycoses*, 62(12), 1140-1147. doi.org/10.1111/myc.13001

Zhou, H. X., Lu, L., Chu, T., Wang, T., Cao, D., Li, F., ... & Feng, S. (2015). Skeletal cryptococcosis from 1977 to 2013. *Frontiers in Microbiology*, 5, 740. doi.org/10.3389/fmicb.2014.00740