

Case Reports

Long COVID-19 Symptoms Remedied by Anti-Viral Treatment in Neurosurgical Patients

Robert Michael Beatty

Neurosurgery, Beatty LLC, Fairway, KS, United States

Article history

Received: 25-04-2023

Revised: 18-07-2023

Accepted: 25-07-2023

Email: rmbattymd@gmail.com

Abstract: The pandemic of COVID-19 is the largest in this century. Aside from the acute infection, some of the patients have been challenged with a complication that is known as long COVID-19. The symptoms of long COVID-19 are extensive and diverse. Long COVID-19 continues to plague many patients post-COVID-19 infection. No universal treatment has been found. This study presents four patients who suffered from long COVID-19. Each patient presented with a different and diverse symptom of long COVID-19. Each of the patient's symptoms resolved or greatly improved upon taking the anti-viral drug acyclovir. Acyclovir has been in use since 1981 and is generally considered safe. A novel theory as to the pathophysiology of long COVID-19 symptoms and the result of a new treatment is presented. The purpose of this study is to provide a foundation for much bigger studies and useful resources for further testing to halt long COVID-19.

Keywords: Long COVID-19, Post COVID Conditions, Long Haul COVID, Post-Acute COVID-19, Long-Term Effects of COVID, Chronic COVID, Post-Acute Sequelae SARS-CoV-2 Infection, PASC, Acyclovir, Treatment COVID-19

Introduction

The COVID-19 outbreak began in December 2019 and by March 2020, the World Health Organization announced that it had reached global pandemic status. This highly contagious and infectious disease created a public health crisis, infecting millions of people and causing a significant number of deaths (Rahman *et al.*, 2021).

As the pandemic entered its second year it became clear that beating the initial infection from the COVID-19 virus was not the end of the story. For many, COVID-19 turned out to be a long-term illness.

The number grew of those suffering from persistent problems after being infected with the COVID-19 virus. By the summer of 2020, the long-term effects of COVID-19 started to be recognized.

"Long COVID-19" is the condition whereby affected individuals do not recover for several weeks or months and in some cases years. It is the condition that follows the onset of symptoms suggestive of COVID-19, whether tested or not (Alwan and Johnson, 2021).

Long COVID-19 syndrome has been defined as signs or symptoms that continue to linger for longer than four weeks after the initial infection. It is also described as being multi-systemic (COVID.gov, 2020). The name "long COVID" was created by the people experiencing it in the spring of 2020 to

describe their journeys of not recovering. Long COVID-19 has many names including Post-COVID Conditions, long-haul COVID, post-acute COVID-19, long-term effects of COVID, and chronic COVID (CDC, 2022). Experts have coined a new term for it, Post-Acute Sequelae SARS-CoV-2 infection (PASC) (Web MD, 2023).

For purposes of this study, the term long COVID-19 will be used. This study presents four long COVID-19 patients whose symptoms clinically resolved or significantly improved by taking acyclovir.

Case Material

Case One

Sixteen-year-old male presented with a history of migraines. The migraines started when he was ten years old. He reported the frequency of the migraine headaches at that time was infrequent.

At the age of 15, playing football he sustained a concussion which was confirmed by his baseline mental test that had been previously performed. Post-concussion, the frequency of headaches increased. The headaches were occurring at the frequency of two to three times per week. The migraine headaches also worsened in severity with halos, change in sleep pattern, nausea, more light sensitivity, and some sound sensitivity.

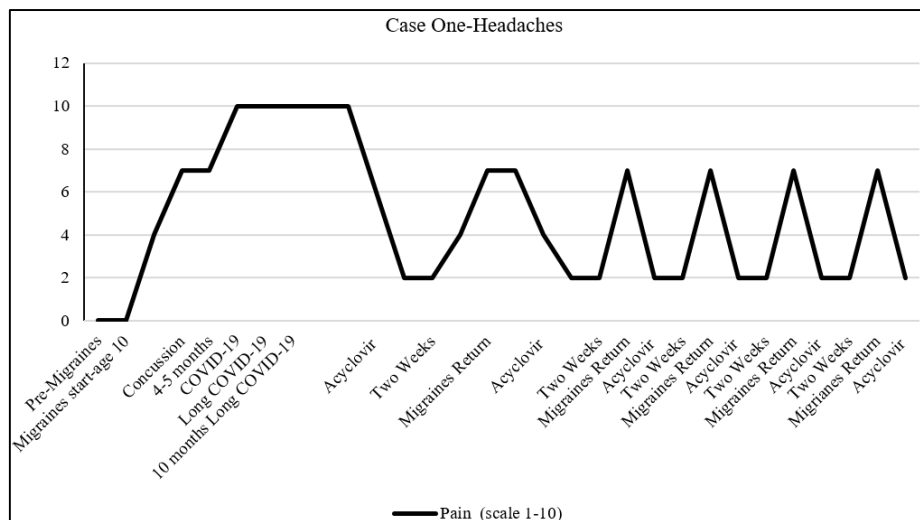


Fig. 1: Case 1. Sixteen-year-old male with a history of migraine sustained concussion followed by COVID-19 infection, headaches increased in intensity and frequency after COVID-19. Acyclovir reduced headaches in intensity and frequency

He went for treatment at the Children’s Hospital Kansas City, MO. At that time, he was prescribed a viscous lidocaine cetirizine regimen and promethazine.

With medication, the patient reported slight improvement.

Four and one-half months after sustaining the concussion, he contracted COVID-19.

Post-COVID-19, the severity and frequency of the migraines increased. The headaches occurred almost daily. With the headaches, he no longer was able to perform daily activities or attend school. Sleep patterns were disrupted. He had daily nausea, vomiting, light sensitivity, and sound sensitivity with the headaches.

He received additional treatment of cetirizine 10 mg daily, Benadryl 25 mg daily, Nerivio, prochlorperazine 5 mg (no more than 3 times per week), amitriptyline 10 mg daily (increased to 35), ondansetron (as needed for nausea), meloxicam, vestibular therapy, Botox injections, and acupuncture.

Headaches persisted at the same frequency and severity with only minimal improvement, for 10 months. The patient continued to be severely limited in all activities and unable to attend school.

At this time, the patient was prescribed acyclovir 800 mg 4 times daily. He took a 5-day course of acyclovir.

Taking the acyclovir he almost immediately improved. The sleep cycle returned to normal. Furthermore, the patient had a notable improvement in the severity and frequency of the headaches. Sound sensitivity disappeared, and light sensitivity greatly diminished as did nausea and vomiting. The headaches diminished to 2-3 per week but he was able to fully function and return to school. The only medication change was the addition of acyclovir.

Once the treatment cycle was completed, the symptoms started to return.

The 5-day course was repeated with a two-week break. This pattern was repeated 6 times. Each time notable improvement occurred with the 5-day treatment of acyclovir and he has been able to be fully functioning. When the acyclovir was discontinued his symptoms would start resurfacing. He is now on a continuous course of acyclovir. The plan is to continue this treatment for 4-6 months with a gradual taper (Fig. 1).

Case Two

Fifteen years ago, a fifty-seven-year-old woman presented with right trigeminal neuralgia. A microvascular decompression was successfully performed at that time. Follow-up and recovery were uneventful with complete resolution of all pain.

The woman contracted COVID-19 in 2020 and within two weeks post recovery of COVID-19, she experienced the return of the facial pain suffered with the trigeminal neuralgia. The pain was as severe as the pain she suffered before the surgery fifteen years prior. Brain MRI was negative.

Acyclovir was prescribed, 800 mg four times daily. Facial pain lessened within 24 h and resolved in 48 h. She finished her 5-day course.

Within a few days of completion of acyclovir treatment her facial pain returned.

Acyclovir was restarted. After the second 5-day course of acyclovir, the facial pain resolved for 10 days. Facial pain returned.

The acyclovir was restarted. Her pain resolved once again. The acyclovir was continued for 4 months. It was then gradually tapered off over ten days.

Facial pain did not return and she has been pain-free for 9 months (Fig. 2).

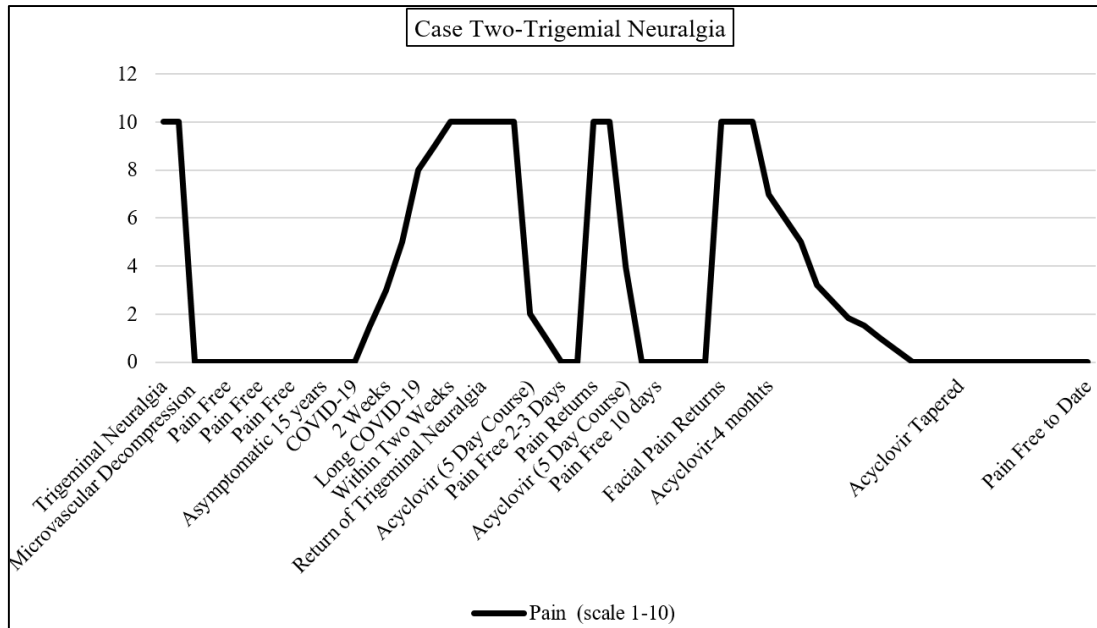


Fig. 2: Case 2, fifty-seven-year-old woman, COVID-19 caused reoccurrence of trigeminal neuralgia after 15 years post microvascular decompression. A prolonged course of acyclovir alleviated the patient's pain

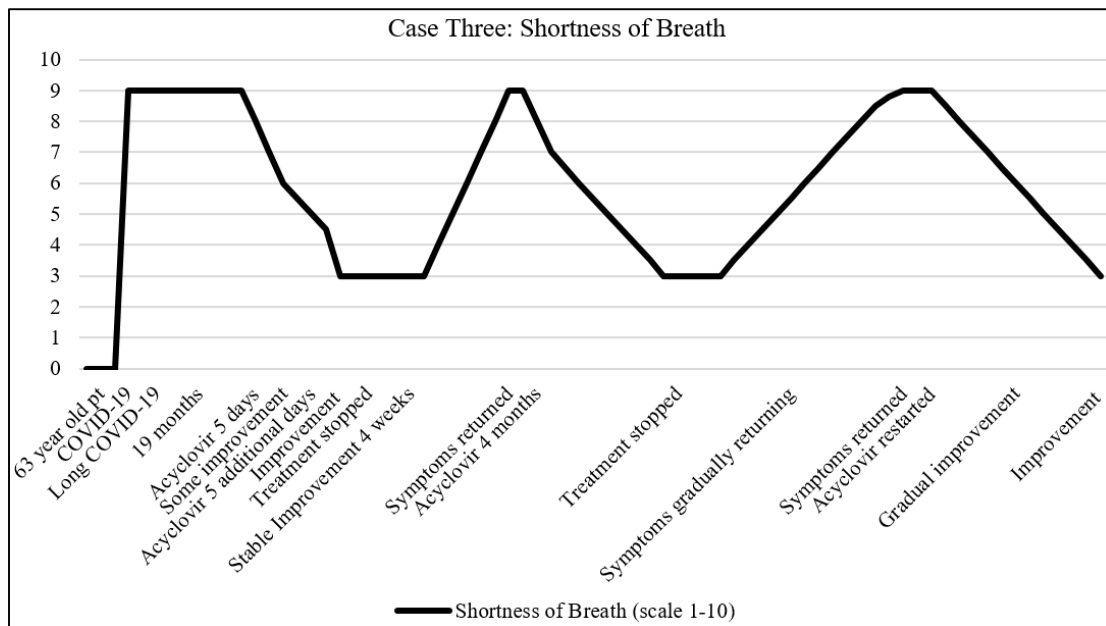


Fig. 3: Case 3 Previously healthy sixty-three-year-old woman developed COVID-19 pneumonia and resultant lung damage. The patient's dyspnea and endurance improved with acyclovir

Case Three

The sixty-three-year-old woman was diagnosed with long COVID-19. Prior to COVID-19 she was a very active tennis player and walked two miles daily. She contracted COVID-19 about one year into the epidemic. COVID-19 largely affected her pulmonary function.

Post-COVID-19 she was unable to do her daily walks without dyspnea and tiredness. She used oxygen nasal prongs at night. Her PO₂ was in the 80's torr. The symptoms of long COVID-19 continued for eighteen months. Acyclovir 800 mg 4 times daily was started for 5 days. At that time, she experienced some improvement. The acyclovir treatment was then continued for another 5 days and she saw continued improvement.

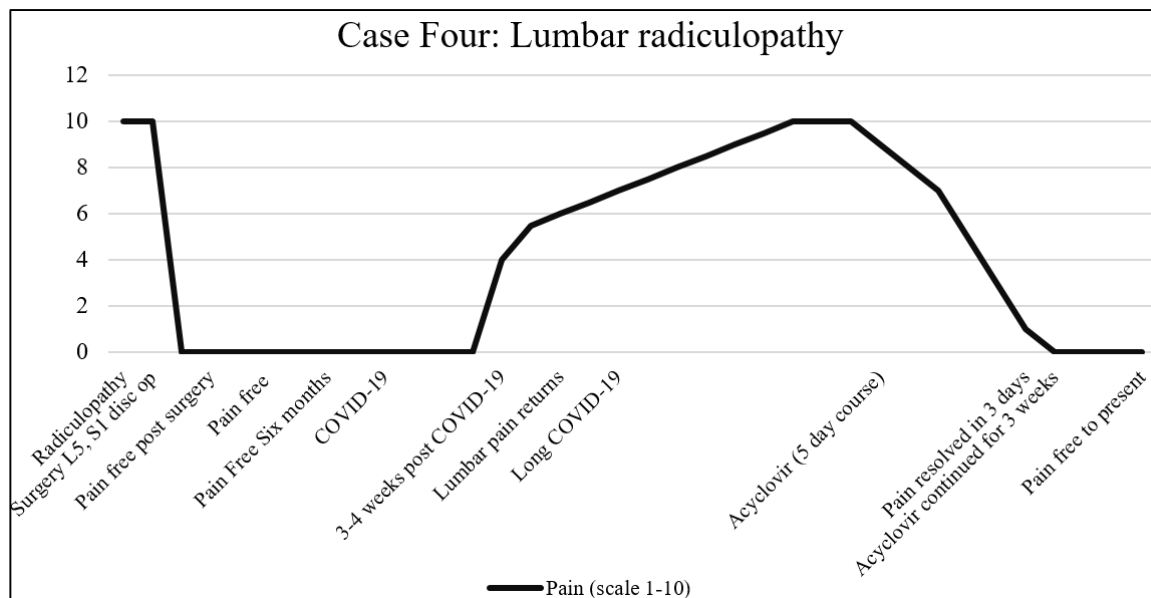


Fig. 4: Case 4. A previously healthy 40-year-old woman was pain-free after an uneventful microdiscectomy. After contracting COVID-19 leg pain returned. Negative lumbar MRI. Acyclovir alleviated leg pain

Treatment stopped and symptoms returned. She restarted the acyclovir and continued with the treatment without stopping the acyclovir and she has returned to walking two miles per day. Her PO₂ is 90 torr. She continued the acyclovir for four months. The acyclovir was tapered over a week and treatment was stopped. Long COVID-19 symptoms gradually returned. Acyclovir was restarted. She again is improving (Fig. 3).

Case Four

A 40-year-old woman underwent lumbar discectomy at L5, S1 for radiculopathy. She developed COVID-19 six months after her lumbar disc surgery. Three to four weeks post-COVID-19 infection, radicular leg pain returned. It was the same pain she had experienced prior to her surgery. MRI of the lumbar spine was negative for disc recurrences.

Acyclovir 800 mg 4 times daily was prescribed. Her leg pain resolved within three days of starting the acyclovir.

The acyclovir was continued for three weeks. The acyclovir was gradually tapered. The leg pain has not returned (Fig. 4).

The PCR COVID-19 test was used to diagnose COVID-19 in all four cases.

Discussion

“As of January 16, 2023, 15 percent of all adults in the US reported having had long COVID-19 symptoms at some point after being infected with COVID-19 and 6% reported current symptoms” (Burns, 2023).

Long COVID-19 is not one condition but a range of conditions with variable risks and outcomes.

Neurologic symptoms are one of the hallmark impairments in long COVID-19 syndromes including headache, vision changes, hearing loss, numbness in extremities, impaired mobility, tremors, memory loss, restless leg syndrome, sleep issues, impaired attention or difficulty concentrating (referred to as "brain fog") and mood changes (NIH, 2019; Bougakov *et al.*, 2021). The American Medical Society reported more than 200 symptoms associated with long COVID-19, but no universal clinical case definition exists (Jennifer, 2022).

Currently there are no treatments designed specifically for long COVID-19. Patients are treated with medications and methods used for other conditions that cause symptoms or complications similar to long COVID-19, i.e., medications to relieve common symptoms such as cough, pain, or headache.

Other common treatments for long COVID-19 include relaxation techniques and gentle activities to help with fatigue and sleep problems and counseling for emotional and mental health problems such as depression or anxiety (Kaiser Permanente, 2023).

Treatment for long COVID-19 is geared to manage the symptoms and rehabilitation (Sutherland, 2023a-b).

Currently, there is no single test that can determine if symptoms are due to COVID-19. No blood test on the market can determine if the SARS-CoV-2 is still active in someone with long COVID-19. Although some studies have detected tiny amounts of virus in the blood, most tests are not able to detect such low amounts. It may be

possible to use highly sensitive techniques such as mass spectrometry to detect (UC Davis Health, 2022).

Researchers at Yale University found long COVID-19 blood samples were also awash with a category of “exhausted” T cells that can be recognized by certain markers they express. Such cells surge in the ongoing presence of pathogens, suggesting “the bodies of people with long COVID-19 are actively fighting something” (Couzin-Frankel, 2022).

The preclinical investigation brought acyclovir to clinical trials in 1977. Acyclovir was approved for medical use in 1981 and the first form of acyclovir (topical) was available to physicians in 1982 (King, 1988). Acyclovir is, in many regards, the prototypic antiviral agent and its use is generally considered safe.

The four long COVID-19 patients presented in this study improved with chronic use of acyclovir. The four patients contracted COVID-19 before Paxlovid was available.

The patients tested positive for COVID-19 with the rapid Polymerase Chain Reaction (PCR) test when the infection began. All patients tested negative when the acute infection ended. To our knowledge, none of the patients had the PCR test during the period of the long COVID-19 symptoms. Even if tested with the PCR test, the patients with long COVID-19 may have insufficient viral mRNA to test positive. Resources to do PCR tests in long COVID-19 patients are limited.

Three of the four patients presented had an injury pre-COVID-19 infection. In the fourth patient, the injury was caused by the COVID-19 infection. Of the four, two patients were post-operative. One underwent a lumbar microdiscectomy for radicular leg pain. The surgery was several months before the COVID-19 infection. The other patient had a craniotomy for trigeminal neuralgia which had occurred 15 years before the COVID-19 infection. The third sustained a concussion playing football superimposed upon a history of migraines before the COVID-19 infection. The fourth patient had pulmonary damage caused by COVID-19 pneumonia.

Injuries induce a complex host response that disrupts immune system homeostasis and may predispose patients to opportunistic infections and inflammatory complications.

Researchers at the national institute of Health found if opportunistic infections arise at time points when there is a wide imbalance in immune response homeostasis, the injured host will be at high risk of developing trauma-associated complications (Stoecklein *et al.*, 2012).

Areas of previous injury may have a weakened immune feedback loop creating unstable homeostasis, and an unstable internal environment. There is an insufficient immune response to the area, and the virus may wax and wane but is not completely destroyed. This weakness allows a localized pocket of virus to exist and persist within the human host.

COVID-19 virus behavior seems similar to the HIV virus in that it is never completely eradicated. COVID-19 lingers, perhaps in pockets that the immune system doesn't easily reach (Stanford Medicine, 2023).

It is theorized that in the four patients presented, the virus triggered a response to the specific area of the body at the site of the patient's previous injury or infection i.e., trigeminal neuralgia, lumbar radiculopathy, post-concussive migraines or dyspnea due to alveolar damage as evidenced by the presented cases.

Acyclovir dampens the virus' replication and thus reduces the inflammatory response hence reducing long COVID-19 symptoms in these patients.

It was observed acyclovir's initial effects came acutely. But it was also observed in each case it required chronic use of the acyclovir on the order of weeks to months to achieve lasting benefit. Relapse of the long COVID-19 symptoms occurred when acyclovir was discontinued in two of the cases to date. Chronic use of acyclovir has not resulted in any observed adverse reactions.

Another study reported four cases depicting the successful use of acyclovir in the treatment of the virus COVID-19. The study reported the treatment with acyclovir resolved their symptoms and lowered their IgG and IgM titers with the treatment (German *et al.*, 2023).

Acyclovir inhibits viral DNA synthesis (Gnann Jr *et al.*, 1983).

Double-stranded DNA (dsDNA) viruses, like Herpes Simplex Virus (HSV), enter the host's nucleus and insert themselves into the host DNA. DNA polymerase works to assemble viral DNA base pairs. Guanine is one of the basic building blocks of DNA and RNA. Acyclovir is structured similarly to guanine, but acyclovir lacks two hydroxyls near the inferior oxygen carbon ring and is in effect "fake" guanine. Once the “fake” guanine is inserted into the viral DNA, the viral replication process ceases.

Single-stranded mRNA (ss mRNA) viruses such as SARS-COVID-19 inject the ss mRNA into the host. Viral replication of the ss mRNA virus can take place one of two ways. One process ss mRNA viral replication takes place is in the host cytoplasm. The ss mRNA virus attaches to the host ribosomes where the viral proteins are transcribed.

Another mechanism in which the ss mRNA virus replicate involves reverse transcriptase. Viral ss mRNA utilizes RNA reverse transcriptase to form DNA. This newly formed viral DNA is incorporated into the host's DNA. DNA polymerase begins the process of assembling base pairs from which viral mRNA is formed. The “fake” guanine base supplied by acyclovir ceases viral replication similar to the pathway utilized by dsDNA viruses, thereby providing a possible explanation by which acyclovir may be effective against ss mRNA, i.e., COVID-19 (Kimberlin and Whitley, 2007).

This study presents a novel theory of sequestered COVID-19 virus in the body. Areas of previous injury may harbor the virus. The virus replicates at a low level which incites a chronic low-level inflammatory response. The low-level inflammatory response to the areas that have been injured or previous trauma results in the symptoms presented in each case of long COVID-19.

The purpose and hope of this study is to provide a foundation for other investigators to further test these observations. Hopefully, it may be used for larger studies to further contribute to the mechanism of long COVID-19 and a resource for further testing to halt long COVID-19.

Conclusion

This study presents case studies of long COVID-19 patients whose symptoms resolved with the chronic use of acyclovir. A novel explanation of the mechanism of symptom resolution is presented. It is the hope other researchers will contribute to this observation.

Acknowledgment

Author has not received any outside support. This article is the sole work of the author.

Funding Information

The author received no funding or financial support. And the author has no conflict of interest.

Ethics

This article is original and contains unpublished material. The corresponding author confirms that all of the other authors have read and approved the manuscript and no ethical issues involved.

References

- Alwan, N. A., & Johnson, L. (2021). Defining long COVID: Going back to the start. *Med*, 2(5), 501-504. <https://doi.org/10.1016/j.medj.2021.03.003>
- Bougakov, D., Podell, K., & Goldberg, E. (2021). Multiple neuroinvasive pathways in COVID-19. *Molecular Neurobiology*, 58(2), 564-575. <https://doi.org/10.1007/s12035-020-02152-5>
- Burns, A. (2023). Long COVID: What Do the Latest Data Show?
- CDC. (2022). Long COVID or post-COVID conditions. *Centers for Disease Control and Prevention*.
- Couzin-Frankel, J. (2022). Long Covid clues emerge from patients' blood. *Science*, 377(6608), 803-803. <https://www.science.org/doi/10.1126/science.ade4427>

- COVID.gov. (2020). What is Long COVID? Washington D. C. (US). <https://www.covid.gov/longcovid/definitions>
- German, E. R., Jairath, M. K., & Caston, J. (2023). Treatment of Long-Haul COVID Patients With Off-Label Acyclovir. *Cureus*, 15(4). <https://doi.org/10.7759/cureus.37926>
- Gnann Jr, J. W., Barton, N. H., & Whitley, R. J. (1983). Acyclovir: Mechanism of action, pharmacokinetics, safety and clinical applications. *Pharmacotherapy: The Journal of Human Pharmacology and Drug Therapy*, 3(5), 275-283. <https://doi.org/10.1002/j.1875-9114.1983.tb03274.x>
- Jennifer, L. (2022). Long COVID: Over 200 symptoms, and a search for guidance, *American Medical Association*. 29 April 2022 [Internet].
- Kaiser Permanente. (2023). Recovering from long-term COVID-19. 10.
- Kimberlin, D. W., & Whitley, R. J. (2007). Antiviral therapy of HSV-1 and-2. *Human Herpesviruses: Biology, Therapy, and Immunoprophylaxis*. <https://www.ncbi.nlm.nih.gov/books/NBK47444/>
- King, D. H. (1988). History, pharmacokinetics, and pharmacology of acyclovir. *Journal of the American Academy of Dermatology*, 18(1), 176-179. [https://doi.org/10.1016/S0190-9622\(88\)70022-5](https://doi.org/10.1016/S0190-9622(88)70022-5)
- NIH. (2019). Coronavirus Disease 2019 (COVID-19) Treatment Guidelines National Institute of Health. <https://www.covid19treatmentguidelines.nih.gov/>
- Rahman, S., Montero, M. T. V., Rowe, K., Kirton, R., & Kunik Jr, F. (2021). Epidemiology, pathogenesis, clinical presentations, diagnosis and treatment of COVID-19: A review of current evidence. *Expert Review of Clinical Pharmacology*, 14(5), 601-621. <https://doi.org/10.1080/17512433.2021.1902303>
- Stanford Medicine. (2023). Stanford Medicine clinical trial goals: Meet long COVID head-on, treat it defeat it.
- Stoecklein, V. M., Osuka, A., & Lederer, J. A. (2012). Trauma equals danger-damage control by the immune system. *Journal of Leukocyte Biology*, 92(3), 539-551. <https://doi.org/10.1189/jlb.0212072>
- Sutherland, S. (2023a). Long COVID Now Looks Like a Neurological Disease, Helping doctors to Focus Treatments. *Scientific American*. 2023; February.
- Sutherland, S. (2023b). The Brain and Long COVID. *Scientific American*. 2023; March: 28-33. <https://doi.org/10.1038/scientificamerican0323-26>
- UC Davis Health. (2022). 11 things doctors have learned about long COVID.
- Web MD. (2023). What is Long COVID (PASC)? <https://www.webmd.com/covid/what-is-long-covid-pasc>