

## Myocardial Motion Analysis of Echocardiography Images using Optical Flow Radial Direction Distribution

Slamet Riyadi, Mohd Marzuki Mustafa and Aini Hussain  
Department of Electrical, Electronic and Systems Engineering,  
Faculty of Engineering and Built Environment, Universiti Kebangsaan Malaysia,  
Bangi 43600 Selangor Malaysia

---

**Abstract: Problem statement:** Myocardial motion is important information for physicians in diagnosing cardiac abnormalities. The motion vector of myocardial can be computed using optical flow technique, which then can be further analyzed based on its magnitude and angle. In practice, physicians are not concern about the angle of vector itself, but are more interested on whether a segment is moving to the center or not. **Approach:** Therefore, in this study we propose a relative motion direction with respect to the center of the cardiac cavity, called radial direction, which is more useful for diagnosis. The radial direction is computed as the difference between the angle of optical flow at a point of interest and the angle between the point and the cavity center. Because of the difficulty in performing analysis based solely on individual vectors, it is helpful to visualize and extract the overall trend by representing motion vectors by their angular distribution. **Results:** This method has been tested on clinical echocardiography sequences and has been shown to be successful in providing a radial direction profile of every segment for each echocardiographic frame. A comparison between the normal angular distribution and the proposed radial direction profile was also presented. **Conclusion:** The proposed profile was shown to be successful in providing the pattern of segmental motion which is easier for physician to analyze the myocardial motion compared with the normal angular distribution as well as more invariant to segment locations.

**Key words:** Echocardiography images, myocardial motion, radial direction, segmental profile, segmental motion, Parasternal Short Axis view (PSAX), Single Photon Emission Computed Tomography (SPECT), cardiovascular disease, Left Ventricular (LV)

---

### INTRODUCTION

In 2004, cardiovascular disease caused 17.1 million deaths, which corresponded to 29% of the global deaths for that year as reported by the World Health Organization (2010). From these data, 7.2 million died because of coronary heart disease, while the rest were affected by stroke. Coronary heart disease, which is also known as “heart attack,” occurs when there is an interruption of blood supply to the heart muscle. It can be detected early by observing abnormality in the motion of the left ventricular. Realizing the importance of this motion, many researchers have focused on the estimation, quantification and interpretation of cardiac motion.

In medical practice, a physician observes the left ventricular motion by means of three main imaging modalities: Single Photon Emission Computed

Tomography (SPECT), Magnetic Resonance Imaging (MRI) and ultrasound imaging. The use of computed tomography and magnetic resonance imaging on the Left Ventricular (LV) motion analysis has been successful because both modalities generate relatively noise-free images (Lin *et al.*, 2006; Sundar *et al.*, 2009). However, they have a number of drawbacks such as invasive, radiation and problems with device portability. In order to overcome these problems, an ultrasound scanning method was introduced; it is a promising tool that has proven to be useful in many clinical applications. Furthermore, many researchers have been attracted on the use of echo images to analyze myocardial motion using block matching method, 3 dimensional model and non-rigid registration (Boukerroui *et al.*, 2003; Papademetris *et al.*, 2001; Ledesma-Carbayo *et al.*, 2005). Other popular methods

---

**Corresponding Author:** Mohd Marzuki Mustafa, Department of Electrical, Electronic and System Engineering,  
Faculty of Engineering and Built Environment, Universiti Kebangsaan, Malaysia Bangi 43600,  
Selangor Tel: +60389216100 Fax: +60389252546

for myocardial motion estimation have been based on the computation of optical flow (Veronesi *et al.*, 2006; Duan *et al.*, 2006; Riyadi *et al.*, 2011).

Current research on the cardiac motion of echo images is mainly focused on the improvement of the accuracy of the motion estimation as there have been difficulties in the detection of motion using echocardiography images. On the other hand, quantification of the computed motion will be very useful for physicians to interpret the cardiac motion for making a clinical decision. Few publications report on quantification and interpretation of computed motion on echo images. Ledesma-Carbayo *et al.* (2005) computed the mean displacement vector and the mean strain tensor of each segment from computed myocardial motion. Both features showed significant differences between normal and abnormal cardiac motion. However, the presented features did not provide a complete segmental profile of cardiac motion in a temporal observation. In another proposed method, Duan *et al.* (2006) developed a four-dimensional optical flow frame-work to track the endocardial surface using real-time 3 dimensional ultrasound. Some features, such as flow magnitude, radial displacement, circumferential displacement, thickening, circumferential and longitudinal stretch and twist, were computed to provide dynamic measurement of cardiac motion. The extracted information was mostly used to visualize real-time 3 dimensional cardiac motion rather than to detect cardiac abnormality.

In clinical practice, a cardiologist does not only need to observe the magnitude of myocardial motion, but also the direction of its motion to ensure an effective LV ejection fraction. Instead of the vector angle itself, in this article we propose a relative motion direction with respect to the center of cavity, called radial direction, which is more useful for diagnosis because this will enable the physician to infer whether a segment is moving to the center or not more clearly. The rest of this study describes the method of optical flow used, the computation of optical flow angle and radial direction and finally we present the comparison of direction profile of optical flow using its angle and proposed radial direction method.

**Understanding LV motion:** For imaging purpose, the American Heart Association has released four standard views for myocardial segmentation and nomenclature. One of them is Parasternal Short Axis view (PSAX) as shown in Fig. 1. In this view, there are six segments of the myocardium which are associated with the distribution of three main coronary arteries. For normal cardiac function, the myocardial segments move inward to the cavity center with uniform displacement from end diastole to end-systole (Anderson, 2007).

**MATERIALS AND METHODS**

The extraction of myocardial motion property based on optical flow involves several steps. They are preprocessing stage, estimation of myocardial motion using optical flow, computation of angle and radial direction and generating the angular distribution profile.

We start with taking two consecutive images of echocardiography sequences. Since it is well-known that echocardiography images contain speckle noise, a quasi Gaussian-Discrete Cosine Transform filter adopted from (Riyadi *et al.*, 2009) is then applied to improve the image quality. Subsequently, we manually select the cavity center and initial points on endocardium and then apply B-spline to generate other points along the endocardium.

After the creation of myocardium boundary, optical flows for every pixel along the endocardial boundary were computed. A statistical averaging approach is implemented to remove outlier data along the boundary and to generate a smoother boundary optical flow vectors. To assist with the interpretation of myocardial motion, we propose a radial direction distribution for each myocardial segment, instead of a single angular distribution of flow vector for all the segments. The radial direction distribution represents a direction pattern

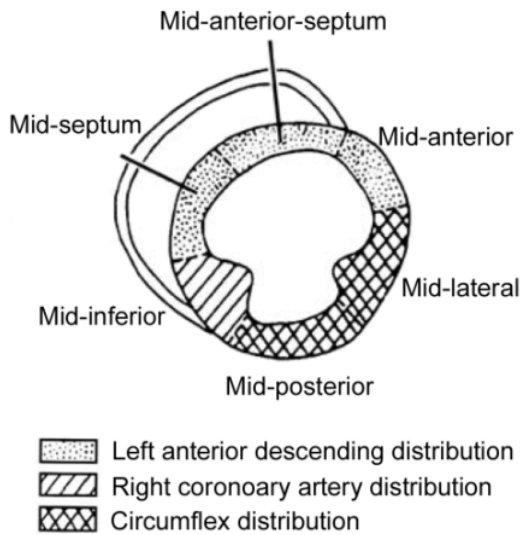


Fig. 1: A standardized PSAX view for an echocardiography image

of segmental myocardial with respect to the cavity center in such a way that cardiologist can directly know the direction in which a segment moves with respect to the centre of the cavity. The rest of this section describes the method used to generate smoothendocardial optical flow and determine radial direction profile.

**Generating smooth endocardial optical flow:** We computed the optical flow between two consecutive frames using Horn-Schunck's method. This method was selected because of its simplicity, low computing time and suitability for estimation of small displacement. To compute optical flow, the intensity of the object is assumed constant. This can be represented as:

$$I(x, y, t) = I(x+\delta x, y+\delta y, t+\delta t) \quad (1)$$

The intensity constraint can be approximated using the 1st order Taylor series expansion since the  $\delta x$ ,  $\delta y$  and  $\delta t$  are within small value, as shown below:

$$I(x + \delta_c, y + \delta_y, t + \delta t) = I(x, y, t) + \frac{\partial I}{\partial x} \delta x + \frac{\partial I}{\partial y} \delta y + \frac{\partial I}{\partial t} \delta t \quad (2)$$

Simplifying Eq. 1 and 2, the basic constraint of the optical flow equation can be articulated as:

$$I_x dx + I_y dy + I_t dt = 0 \text{ or } I_x u + I_y v + I_t = 0 \quad (3)$$

Horn-Schunck's method introduces global smoothness error ( $E_s$ ) and brightness constancy error ( $E_c$ ) defined as (Horn and Schuck, 1981):

$$E_s = \iint \left( \left( \frac{\partial u}{\partial x} \right)^2 + \left( \frac{\partial u}{\partial y} \right)^2 + \left( \frac{\partial v}{\partial x} \right)^2 + \left( \frac{\partial v}{\partial y} \right)^2 \right) dx dy \quad (4)$$

$$E_c = \iint (u \nabla_x + v \nabla_y + \nabla_t)^2 dx dy \quad (5)$$

In terms of motion estimation, pixels should not have abrupt changes in magnitude and direction of their vector flow compared with the adjacent pixels. Certain points in the neighborhood that have obviously different magnitudes or directions can be considered as errors due to miscomputation of optical flow. To smooth the variation of the vectors in a neighborhood, we apply statistical averaging to remove the outlier data along the boundary. The outlier data on the neighboring points are successively removed and replaced by the average of neighboring vectors. Figure 2a and b show

an example of computed optical flow before and after the smoothing process, respectively.

**Determining radial direction:** The two parameters of a motion vector are its magnitude and angle. The vector magnitude represents the displacement of a pixel for two consecutive frames, while the vector angle is its direction in terms of the axial (u) and the ordinal (v) component. The vector angle  $\theta_1$  is computed using:

$$\theta_1 = a \tan 2(v_1, u_1) \quad (6)$$

In mathematics, the two-arguments function  $\text{atan2}(y, x)$  is a variant of the arctangen function, which calculates an angle (in radians) between the positive x-axis and a point given by coordinate (x, y). Following the standard mathematical convention,  $\text{atan2}$  function results angles that increase counter-clockwise. However, since the optical flow computation uses clockwise convention, the vector angle of optical flow  $\theta_1$  also follows the clockwise convention as shown in Fig. 3. The  $\text{atan2}$  function produces results in the range  $(-\pi, \pi]$  that can be convert to  $[0, 2\pi)$  by adding  $2\pi$  to negative value of  $\theta_1$ .

In clinical diagnoses, the physician usually does not use the vector direction to analyze the myocardial motion. The direction of the vector with respect to the center of the cavity is more useful information because the physician observes whether a segment moves to the center of the cavity or not. Therefore, in this study, we introduce a new motion property, which is called radial direction defined as the direction of a motion vector with respect to the center of the cavity as illustrated in Fig. 3. The radial direction  $\alpha$  of a point of interest ( $x_i, y_i$ ) is the difference between the angle of optical flow at the point of interest ( $\theta_1$ ) and the angle between the point and the cavity center ( $\theta_2$ ), or defined as:

$$\alpha = \theta_1 - \theta_2 \quad (7)$$

where, the angle  $\theta_2$  can be calculated by the following equation:

$$\theta_2 = a \tan 2(y_c - y_i, x_c - x_i) \quad (8)$$

The Eq. 7 produces radial direction values in the range  $(-2\pi, 2\pi)$ . To make the value simpler and more informative, we normalize this value using the following rules:

$$\theta_2 = \begin{cases} \theta_2 & \text{if } -\pi \leq \theta_2 \leq \pi \\ \theta_2 + 2\pi & \text{if } -2\pi \leq \theta_2 < -\pi \\ \theta_2 - 2\pi & \text{if } \pi > \theta_2 \geq 2\pi \end{cases} \quad (9)$$




Fig. 2: Example of boundary vectors on a segment (a) before and (b) after the smoothing process

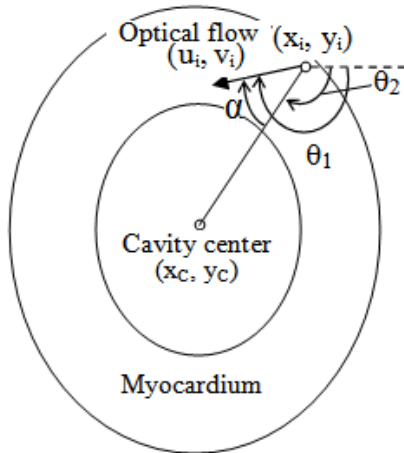


Fig. 3: Radial direction of an optical flow

therefore the radial direction angle  $\alpha$  will be in the range  $(0, \pi)$ . The 0 means that the optical flow direction is towards the cavity center whereas the  $\pi$  indicates the opposite direction.

To facilitate the interpretation of myocardial motion, we generated the distribution of radial direction for every segment for each frame. This distribution shows the pattern of direction in such a way that a

physician will be able to quickly recognize the direction to which a segment moves.

## RESULTS

**Smoothed endocardial optical flow:** Our proposed method was tested with a set of clinical echocardiography data, which were previously recorded by a physician. The data were acquired on a parasternal short axis standard view using a Siemens Acuson Sequoia scanner with a 25 frame rate. Manual interpretations on the recorded data have been also performed by two cardiologists to provide manual diagnosis on the myocardial motion. At the end, this manual diagnosis will be used to validate the result obtained by the proposed method. Figure 4 shows an example of four frames of ten consecutive sequences of PSAX view echocardiography images. We then computed the optical flow vectors of two consecutive images (frames 2 and 3) and applied the proposed method to these optical flow vectors.

In the Materials and Methods, we have seen that smooth and correct directions were obtained for the pixels located on the endocardium, whereas many incorrect optical flow vectors occurred inside the myocardium. For this reason, we should extract only the optical flow vectors on the endocardium to provide the myocardial motion profile precisely. Prior to extracting the endocardial features, we have to manually select a few points distributed along the boundary of the cavity and then generate other points along the boundary using the B-spline algorithm as shown in Fig. 5a and b, respectively. In the next stage, the vector flows on the boundary were obtained by averaging  $5 \times 5$  neighboring vector flows along the boundary and then smoothed as shown in Fig. 5c.

**Distribution of radial direction:** To illustrate the mid-anterior-septum (upper center segment) of Fig. 5c, the zoomed image of the motion vectors and their angle distribution are shown in Fig. 6a and c, respectively. This angle distribution shows that these vectors have dominant directions in the interval  $70-90^\circ$ . The standard vector angle convention follows a clockwise direction orientation where  $0, 90, 180$  and  $270^\circ$  indicate the right, down, left and up direction, respectively. According to this convention, a segment with the dominant directions in the interval  $70-90^\circ$  moves downward to the center. Similarly, Fig. 6d shows an angle distribution of the mid-posterior (lower center segment) in Fig. 6b. The dominant direction is in the interval  $250-290^\circ$  and it indicates that part of the segment moves upward to the center.

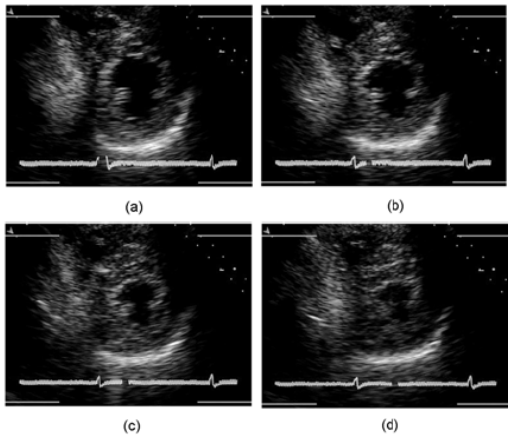


Fig. 4: Four frames of cardiac motion from end-diastole to end-systole: (a) 1st, (b) 4th, (c) 7th and (d) 10th frame

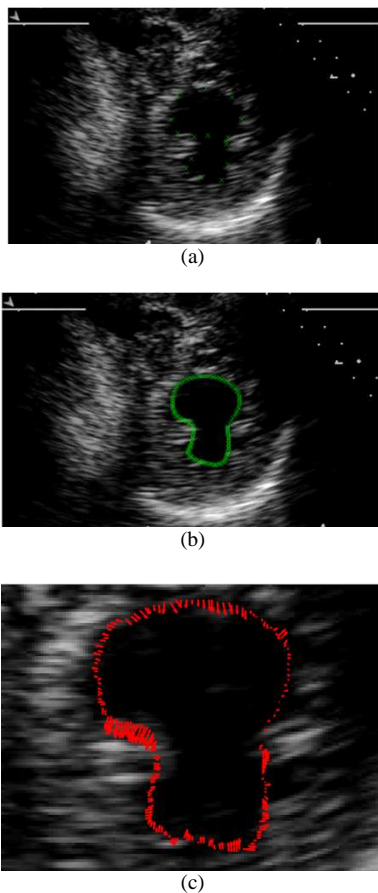


Fig. 5: (a) Selected cavity center and initial points on The 2nd frame; (b) continuous points along the boundary and (c) a smoothed vector flow using a statistical approach

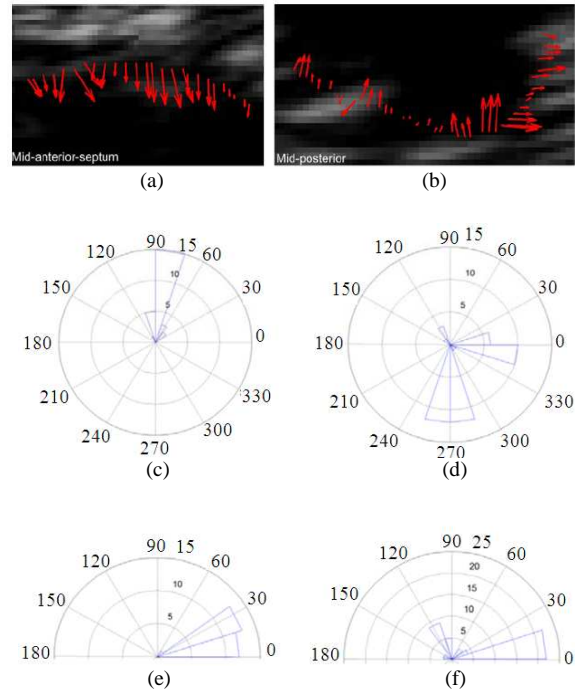


Fig. 6: Example of the usefulness of providing the distribution of radial direction compared with the vector angle distribution for the mid-anterior-septum (first column) and mid-posterior (second column) segment: (a) and (b) the zoomed image of the motion vectors, (c) and (d) the vector angle distribution and (e) and (f) the radial direction distribution

## DISCUSSION

These two examples in Fig. 6a-c and b-d show that although the value of dominant directions is largely different, both segments move towards the center. In other words, because the location of mid-anterior-segment is on the upper center of myocardial, physician should remember that it will move towards the center only if the angle direction is nearby  $90^\circ$ . For the mid-posterior which is on the lower center segment, it moves towards the center if the dominant direction is about  $270^\circ$ . To enable such an inference to be made, it is necessary for the physician to remember the angle convention and also the parts of the cardiac segment that are being referred to. Hence, it is not easy to correlate the angle distribution and the center-directed motion for a particular cardiac segment.

If we evaluate the distributions of motion vector based on radial direction Fig. 6e and f, they are easier for a physician to analyze myocardial motion instead of the angle of the vector flow itself. These figures show

that both segments which move towards the center have a same dominant angle, i.e., in the interval  $0^\circ$  and  $30^\circ$ . Physicians do not need to remember the angle convention and also the location of the segment of interest. They just to know a simple convention that a  $0^\circ$  radial direction means the vector moves to the center of the cavity whereas a  $180^\circ$  radial direction means that the vector is moving to the opposite direction of the cavity center. We conclude that the radial direction is more invariant to the segment location because we have considered the vector location with respect to the center in the computation of the radial direction. Additionally, using this orientation, the pattern of segmental motion direction can be simply obtained by considering the dominant value of the radial direction distribution.

### CONCLUSION

A new myocardial segmental motion property based on radial direction has been described.. The radial direction is computed by considering the angle of optical flow at a point of interest and the normal angle between the point and the cavity center. The individual radial direction along the boundary is then used to generate a radial direction profile for every myocardial segment of each frame. The result shows that the radial direction profile is easier for physician to analyze the myocardial motion instead of normal angular distribution as well as more invariant to segment locations.

### ACKNOWLEDGEMENT

Researchers would like to acknowledge the University Kebangsaan Malaysia (UKM-GUP-TKP-08-24-080) for the financial support for this research. We also thanks to Oteh Maskon and Ika Faizura Mohd Nor, who are with the Cardiac Care Unit, Medical Center, Universiti Kebangsaan Malaysia, for providing the cardiac image data and their continuous discussions on the visual analysis and interpretation of the cardiac motion.

### REFERENCES

Anderson, B., 2007. The Normal Examination and Echocardiographic Measurements. 1st Edn., Blackwell Publishing, ISBN-10: 0646468634, pp: 51.  
Boukerroui, D., J.A. Noble and M. Brady, 2003. Velocity estimation in ultrasound images: A Block Matching Approach, LNCS, 2732: 586-598, DOI: 10.1007/978-3-540-45087-0\_49

Duan, Q., E.D. Angelini, O. Gerard, K.D. Costa and J.W. Holmes *et al.*, 2006. Cardiac motion analysis based on optical flow on real-time three-dimensional ultrasound data. Recent Advances in Diagnostic and Therapeutic Ultrasound Imaging for Medical Applications, pp: 707-710. <http://medimage.bme.columbia.edu/images/publications/413-pdf.pdf>  
Horn, B.K.P and B.G. Schuck, 1981. Determining optical flow. Artificial Intell.. 9: 185-203. DOI: 10.1016/0004-3702(81)90024-2  
Ledesma-Carbayo, M.J., J. Kybic, M. Desco, A. Santos and M. Suhling *et al.*, 2005. Spatio-temporal nonrigid registration for ultrasound cardiac motion estimation. IEEE Trans. Med. Imag., 24: 1113-1126. DOI: 10.1109/TMI.2005.852050  
Lin, G.S., H.H. Hines, G. Grant, K.Taylor and C. Ryals, 2006. Automated quantification of myocardial ischemia and wall motion defects by use of cardiac SPECT polar mapping and 4-D surface rendering. J. Nuclear Med. Technol., 34: 3-17. <http://tech.snmjournals.org/cgi/reprint/34/1/3.pdf>  
Papademetris, X., A.J. Sinusas, D.P. Dione and J.S. Duncan, 2001. Estimation of 3D left ventricular deformation from echocardiography. Med. Image Anal., 5: 17-28. DOI: 10.1016/S1361-8415(00)00022-0  
Riyadi, S., M.M. Musatafa, A. Hussain, O. Maskon and I.F.M. Noh, 2011. Enhanced Optical Flow Field of Left Ventricular Motion using Quasi Gaussian DCT Filter. In: Software Tools and Algorithms for Biological Systems, Arabnia, H.R. (Ed.). Series: Advances in Experimental Medicine and Biology, pp: 461-469. DOI: 10.1007/978-1-4419-7046-6\_46  
Riyadi, S., M.M. Musatafa, A. Hussain, O. Maskon and I.F.M. Noh, 2009. Quasi-Gaussian DCT Filter for speckle reduction of ultrasound images. LNCS, 5857: 136-147. DOI: 10.1007/978-3-642-05036-7\_14  
Sundar, H., H. Litt and D. Shen, 2009. Estimating myocardial motion by 4D image warping. Patt. Recog., 42: 2514-2526. DOI :10.1016/j.patcog.2009.04.022  
Veronesi, F., C. Corsi, E.G. Cainai and C. Lamberti, 2006. Tracking of left ventricular long axis from real-time three-dimensional echocardiography using optical flow techniques. IEEE Trans. Inform. Technol. Biomed., 10: 174-181. DOI: 10.1109/TITB.2005.855535  
World Health Organization, 2010. Cardiovascular Diseases. <http://www.who.int/mediacenter/factsheets/fs317/en>