

Original Research Paper

Hepato and Nephrotoxicity Caused by Sub-Chronic Exposure to Relevant Concentrations of Human Exposure to Glyphosate-Based Herbicide: An Experimental Study in Rats

¹Fernanda de Maria Serra, ²Leticia Rocha Magalhães, ²Beatriz Bertholace Magalhães Silva, ²Emmanuela Beatriz Vantini Barreiro, ²Isabela Benes Franco, ²Isabela Melo Nogueira, ³Liliane Aparecida Tanus Benatti, ¹Rogério Giuffrida and ^{1,2,4}Gisele Alborghetti Nai

¹Graduate Program in Animal Science, Universidade do Oeste Paulista (UNOESTE), Presidente Prudente, SP, Brazil

²Medical College, Universidade do Oeste Paulista (UNOESTE), Presidente Prudente, SP, Brazil

³Department of Physiology, Health Sciences Center, Universidade do Oeste Paulista (UNOESTE), Presidente Prudente, SP, Brazil

⁴Department of Pathology, Medical College, Universidade do Oeste Paulista (UNOESTE), Presidente Prudente, SP, Brazil

Article history

Received: 10-04-2023

Revised: 18-07-2023

Accepted: 04-09-2023

Corresponding Author:

Gisele Alborghetti Nai

Department of Pathology,

Medical College, Universidade

do Oeste Paulista (UNOESTE),

Presidente Prudente, SP, Brazil

Email: patologia@unoeste.br

Abstract: Glyphosate's remarkable effectiveness in weed control has made it among the foremost widely employed herbicides globally. Several Glyphosate-Based Herbicides (GBHs) contain 1-4 dioxane, a compound known to induce cancer in animals and potentially contribute to liver and kidney damage in humans. The objective was to assess the liver and kidney toxicity resulting from sub-chronic exposure to GBH in rats. Eighty wistar rats were divided into 8 groups, each consisting of 5 males and 5 females. These groups were categorized into 4 inhalation exposure groups and 4 oral exposure groups. The control groups were subjected to exposure to sodium chloride solution, while the other groups were exposed to GBH at low, medium, and high concentrations. This exposure continued for 75 days. Blood samples were taken for the assessment of Aspartate Aminotransferase (AST), Alanine Aminotransferase (ALT), creatinine, and urea levels, and the liver, kidney, pancreas and spleen tissues were sampled for histopathology. The females in the high oral concentration group exhibited the most elevated levels of AST, ALT, and urea ($p < 0.05$). Liver steatosis was observed in all animals exposed to medium and high GBH concentrations ($p < 0.05$). Tubular changes were evident in all GBH-exposed animals. Furthermore, animals submitted to a high GBH concentration displayed an increased count of nucleoli-organizing regions in the liver and kidney ($p < 0.05$). High-concentration exposure to GBH, mainly orally, causes greater liver and kidney damage. Females had more pronounced hepatic and renal biochemical changes than males.

Keywords: Occupational Exposure, Exposure to Chemicals, Exposure to Pesticides, Inhalation Exposure, Dietary Exposure

Introduction

In the past decades, significant global modernization was linked to advances in technology for large-scale production. This progress has been reflected in agriculture, leading to intense use of pesticides (Pingali, 2012). Herbicides, a type of pesticides, are used by livestock producers and food industries and for personal hygiene and domestic applications to combat weeds (Benbrook, 2016); however, herbicides can have several effects on living beings (Landrigan and Belpolgi, 2018).

Glyphosate is an organophosphate, systemic, and nonselective herbicide used to kill various species of grasses, broadleaf, and reeds (Sribanditmongkol *et al.*, 2012). Glyphosate herbicides are the primary pesticides employed on a global scale, currently being utilized on roughly 24% of the world's total arable land (Tang *et al.*, 2017), mainly in rice, corn, soybean, horticulture, viticulture, and forestry (Topal *et al.*, 2015). Additionally, Glyphosate-Based Herbicides (GBH) are widely used in domestic and urban gardens, such as squares and parks (Mesnage *et al.*, 2015a; Topal *et al.*, 2015; Tang *et al.*, 2017).

GBH residues are frequently identified in food and drinking water, often as a result of groundwater contamination; these factors increase exposure routes for the general population in addition to farmers (Mesnage *et al.*, 2015a; Topal *et al.*, 2015; Tang *et al.*, 2017). Thus, not only glyphosate but also its metabolites are prevalent among the population (Mesnage *et al.*, 2015a).

The US Environmental Protection Agency (USEPA) categorizes glyphosate and its primary metabolite, Aminomethylphosphonic Acid (AMPA), as belonging to toxicity category IV (signifying very low acute toxicity in typical usage) (Sribanditmongkol *et al.*, 2012; Wunnapuk *et al.*, 2014) based on the manufacturer's assertion that glyphosate does not present hazards to human health or the environment when employed following the product leaflet instructions (Sribanditmongkol *et al.*, 2012).

Studies in laboratory and farm animals showed that the doses of glyphosate and AMPA in kidney and liver tissues significantly exceed those found in other tissues, ranging from 10-100 times higher German federal agency (BfR, 2014). A study in farm animals showed that elevated urinary levels of glyphosate correlate with the changes in parameters indicative of hepatic and renal oxidative stress (Krüger *et al.*, 2013). Thus, the liver and kidney stand as vulnerable organs to glyphosate's impact.

Olorunsogo *et al.* (1979) were the first to describe the possible hepatic effects of glyphosate. Numerous research studies have demonstrated the potential for glyphosate and its commercial formulations to induce toxic effects, primarily affecting the liver and kidneys (Mesnage *et al.*, 2015b). Nevertheless, these investigations often employed higher doses and modes of exposure not reflective of typical human conditions.

The objective was to assess the hepatic and renal toxicity resulting from sub-chronic exposure to GBH in a murine model, by simulating environmental exposure. Additionally, we aimed to analyze potential disparities between the primary routes of human exposure (inhalation and through contaminated food) and explore gender-based variations.

Materials and Methods

Animals

The ethics committee on animal use of the institution where the study was carried out granted approval for this study (protocol no. 3792). The treatment of the animals in

the study adhered to institutional protocols and followed globally recognized principles for the ethical use and welfare of laboratory animals, with an emphasis on minimizing suffering and distress.

The 'pwr' package, as part of the R software (Team, 2023), was utilized to calculate the required minimum sample size for comparing scores for 8 groups. The findings suggest that a minimum of 8 animals per group is required. Adding 15% more elements, to a possible non-parametric distribution, we chose to use 10 per group.

Eighty adults (at the commencement of the experiment, the animals were 90 days old) albino Wistar rats (40 male and 40 female) weighing 200-250 g were utilized in the study. The animals were accommodated in separate plastic cages, separated by gender, within a climate-controlled vivarium with regulated temperature and humidity and subjected to a 12 h light-dark cycle.

The animals were randomly allocated to eight groups, each consisting of 5 males and 5 females. Two groups served as control groups, receiving sodium chloride (NaCl) exposure, while the remaining six groups were subjected to varying concentrations of GBH as per the product insert instructions. The concentration for each group was adjusted according to the cage area; this approach aimed to replicate environmental exposure, encompassing both occupational and dietary aspects Table 1.

Protocol of GBH Exposure

Exposure was performed using this formulation of GBH [N-(phosphonomethyl) glycine] (Roundup Original DI, Monsanto, São Paulo, Brazil): Diammonium salt of N-(phosphonomethyl) glycine (Glyphosate): 445 g/L (44.5% m/v); N-(phosphonomethyl) glycine (Glyphosate) acid equivalent: 370 g/L (37.0% m/v); other ingredients: 751 g/L (75.1% m/v).

To facilitate nebulization, we employed two chambers measuring 32×24×32 cm each, linked to a nebulizer (Pulmosonic Star®, Soniclear Ind. Com. Imp. and Exp. Ltda., São Paulo, Brazil), with sodium chloride (NaCl) as the chosen vehicle, utilizing 10 mL. The exposure time was approximately 15 min to nebulize the entire solution (for animals and for feed) (Mello *et al.*, 2018).

Table 1: Distribution of the study groups evaluated

Groups	Concentration of exposure	Inhalation exposure	Oral exposure
Control	Sodium chloride (NaCl) only	G1	G2
Low GBH [#] concentration	3.71×10 ⁻³ g.a.i./ha* (corresponding to 187.17 mg/m ³)	G3	G4
Medium GBH concentration	6.19×10 ⁻³ g.a.i./ha (corresponding to 313.31 mg/m ³)	G5	G6
High GBH concentration	9.28×10 ⁻³ g.a.i./ha (corresponding to 467.93 mg/m ³)	G7	G8

[#]: Glyphosate-based herbicide; *g.a.i./ha: Grams of active ingredient per hectare

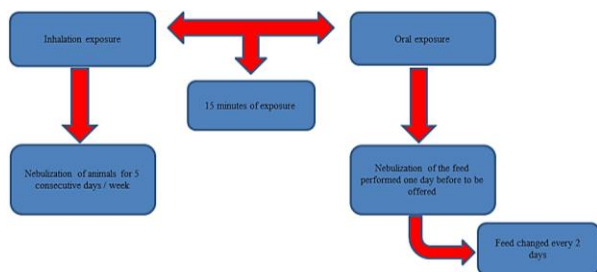


Fig. 1: Design of nebulization of animals and feed

Animals exposed through inhalation were nebulized for five consecutive days each week, simulating occupational exposure. Those exposed orally had their food nebulized one day before consumption (Fig. 1) (Bonfim *et al.*, 2020). The animal feed in all groups was replenished every two days and the remaining feed was weighed during each replenishment. The animals' initial and final weights were recorded at the start and conclusion of the 75-day exposure period.

Anesthesia and euthanasia were conducted using sodium thiopental (Syntec, Santana do Parnaíba, SP, Brazil) at doses of 40 and 100 mg/kg, respectively, administered via the peritoneal cavity (Paiva *et al.*, 2005).

Biochemical Analysis

Blood collection was conducted following anesthesia by intracardiac puncture using a BD Vacutainer® (Becton, Dickinson and Company, USA). Five milliliters of blood were obtained for the subsequent laboratory tests, including AST (aspartate aminotransferase), ALT (alanine aminotransferase), creatinine, and urea. All biochemical analyses were carried out using an automated COBAS C111 device (Roche, USA).

Histopathological Analysis

Following euthanasia, the liver, kidney, pancreas, and spleen were extracted from each animal. The excised tissues were preserved in 10% buffered formaldehyde (Cinética Indústria Química, São Paulo, Brazil) for 24 h and subsequently underwent standard histological processing, involving paraffin embedding (Dinâmica Analytical Reagents, São Paulo, Brazil). Consecutive 5 µm sections were generated employing a LEICA RM 2265 microtome (Leica Biosystems Nussloch GmbH, Germany) and stained with the Haematoxylin-Eosin (HE) method (Dolles, São Paulo, Brazil).

A blinded analysis was carried out with an optical microscope (NIKON Labophot, Japan). The parameters analyzed in the liver, kidney, pancreas and spleen included inflammatory infiltrate (absent; mild= 1 to 3 foci; moderate = 4-6 foci; severe = 7 or more foci) and type (mononuclear and/or polymorphonuclear); tissue

congestion (number of dilated and congested vessels: Mild = 1-10 vessels = mild; moderate = 11-20 vessels; severe = more than 20 vessels); tissue necrosis (percentage of compromised area); vascular necrosis (number of vessels affected); dysplastic lesions and its grade (mild, moderate or severe); and neoplastic lesions (benign or malignant) (Pegoraro *et al.*, 2021).

The following parameters were also specifically analyzed in each organ (Pegoraro *et al.*, 2021) liver: Presence (absent or present) and type of steatosis (microvesicular and/or macrovesicular), cholestasis (absent or present), tissue fibrosis (ranked second to Metavir's classification) and cirrhosis; kidney: Tubular alterations (oedematous degeneration or tubular necrosis) (focal and diffuse); glomerular lesion (number of glomeruli affected); thickening of the vessels' basement membrane (absent or present); and cylinders (absent or present and type); pancreas: Fibrosis (percentage of compromised area); acinar atrophy (percentage of compromised area); and injury of the islets of Langerhans (percentage of compromised area); spleen: Hyperplasia of the white pulp (absent or present); hyperplasia of the red pulp (absent or present); and fibrosis (percentage of compromised area).

In addition, liver sections were subjected to Perls stain (Merck, Darmstadt, Germany) to assess the histological presence of iron storage within hepatocytes. (Hepatocytic iron score from 0-36, in each Rappaport area, according to granules size), sinusoidal spaces (Sinusoidal iron score from 0-12, in each Rappaport area, according to granules size) and portal space (Portal iron score from 0-12, according to the percentage of iron-overloaded macrophages, biliary cells, and vascular wall) (Deugnier and Turlin, 2007).

Argyrophilic Nucleoli-Organizing Region (AgNOR) Staining

The deparaffinized liver and kidney sections were immersed in a silver nitrate solution, shielded from light, within a humid chamber, for 40 min at 60°C. Following this, the specimens were rinsed in deionized water at 45°C and the sections were subsequently counterstained with van Gieson's ("light green") stain (Merck, Darmstadt, Germany) for a period of 3 min (Ploton *et al.*, 1986).

Nucleoli-Organizing Regions (NORs) were quantified in the nuclei of 10 cells/High Power Field (HPF) in 10 fields, totaling 100 cells (hepatocytes and renal tubular cells) in each animal (Ploton *et al.*, 1986).

Statistical Analysis

Variables represented as scores were treated as non-parametric. The normality assumption of continuous variables was assessed using the Shapiro-Wilk test. Non-parametric variables were compared between genders

through the Mann-Whitney test and between groups utilizing the Kruskal-Wallis test, followed by Dunn's test for multiple comparisons. All statistical analyses were carried out with the R package (Team, 2023). Significance for between-group distinctions was determined at a p-value of <0.05.

Results

During the study, one female from the oral control group died because of an infection of the ear canal.

Animal Weight and Feed Intake

The initial and final weights of the animals differed between genders ($p = 0.007$) and were lower in females in all groups (exposed and unexposed to GBH). There were no differences between the exposed and unexposed groups ($p = 0.29$) and between the routes of exposure to GBH (oral and inhaled) ($p = 0.46$).

No statistically significant difference was observed in food consumed among the groups under investigation ($p = 0.703$) or between genders ($p = 0.15$).

Biochemical and Histopathological Analysis of Organs

Liver

Males of the G3 group and females of the G5 and G8 groups had the highest serum AST concentrations ($p = 0.015$) (Fig. 2A). Groups G7 and G8 had the highest serum concentrations of ALT ($p = 0.02$) and they were higher in females than in males ($p = 0.05$) (Fig. 2B) (Table 2).

Tissue fibrosis, cholestasis, liver cirrhosis, tissue necrosis, vascular necrosis, dysplastic or neoplastic lesions, and iron deposits were not detected.

Mild inflammation characterized by focal lymphocytic infiltration was observed only in one female animal of the G5 group and two male animals of the G7 group ($p = 0.0514$).

Diffuse liver steatosis was observed in all animals exposed to medium and high GBH concentrations despite the route of exposure and gender of the animals and in 80% of the animals of the G3 group, predominantly in males ($p = 0.034$) (Figs. 3-4).

Higher concentrations of the herbicide corresponded to higher NOR numbers in hepatocytes ($p = 0.001$) (Table 3) and oral exposure exhibited a higher count of NORs than that in animals exposed by the inhalation ($p = 0.001$). No gender-based disparities were detected in the NOR numbers ($p = 0.3465$).

Kidney

The creatinine concentration did not differ between genders ($p = 0.177$). Females had a higher concentration of urea than males ($p = 0.01255$) (Fig. 5). The animals

exposed by inhalation showed no differences in creatinine ($p = 0.47$) and urea ($p = 0.524$). The groups orally exposed showed differences in the creatinine levels between G8 × (G2, G4, G6) ($p = 0.02$) and in the levels of urea between G2 and G8 ($p = 0.0119$) (Table 2).

Necrosis (tissue and vascular), glomerular lesions, and thickening of the basement membrane of vessels and cylinders were not observed.

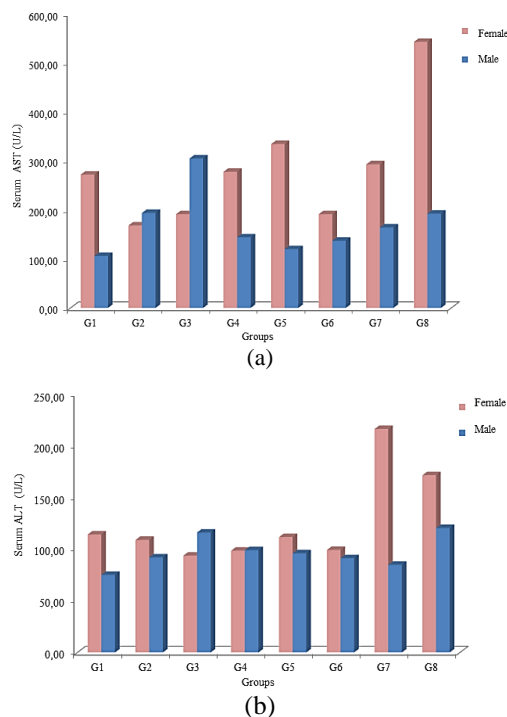


Fig. 2: Mean serum concentrations in the tested groups and male and female animals ($n = 79$); A-AST (aspartate aminotransferase) (U/L); B-ALT (alanine aminotransferase) (U/L). Groups: G1: Inhalation control; G2: Oral control; G3: Low inhalation concentration; G4: Low oral concentration; G5: Medium inhalation concentration; G6: Medium oral concentration; G7: High inhalation concentration; G8: High oral concentration

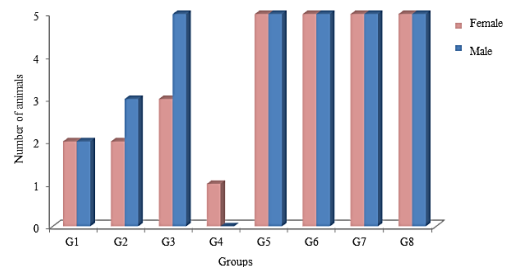


Fig. 3: Incidence of hepatic steatosis in the tested groups and in male and female animals ($n = 79$). Groups: G1: Inhalation control; G2: Oral control; G3: Low inhalation concentration; G4: Low oral concentration; G5: Medium inhalation concentration; G6: Medium oral concentration; G7: High inhalation concentration; G8: High oral concentration

Table 2: Mean (\pm standard deviation) of the serum concentration of ALT (U / L), AST (U / L), creatinine (mg / dL), and urea (mg / dL) per study group, regardless of the gender of the animals (n = 79)

Groups	AST	ALT	Creatinine	Urea
G1	188.97(\pm 125.03) ^a	94.67(\pm 34.40) ^a	0.33(\pm 0.05) ^a	46.05(\pm 6.71) ^a
G2	182.37(\pm 88.77) ^a	99.57(\pm 32.26) ^a	0.33(\pm 0.07) ^a	46.68(\pm 8.47) ^a
G3	248.03(\pm 201.38) ^b	104.94(\pm 52.14) ^a	0.32(\pm 0.06) ^a	46.38(\pm 6.53) ^a
G4	210.87(\pm 95.77) ^a	98.82(\pm 06.72) ^a	0.32(\pm 0.04) ^a	52.72(\pm 7.09) ^{a,b}
G5	227.03(\pm 194.72) ^b	105.16(\pm 39.35) ^a	0.34(\pm 0.05) ^a	47.73(\pm 6.00) ^a
G6	164.14(\pm 49.95) ^a	95.19(\pm 15.82) ^a	0.30(\pm 0.04) ^a	53.02(\pm 6.38) ^{a,b}
G7	228.54(\pm 97.02) ^b	150.59(\pm 133.70) ^b	0.35(\pm 0.05) ^a	43.43(\pm 6.83) ^a
G8	367.47(\pm 233.56) ^c	146.06(\pm 54.01) ^b	0.40(\pm 0.09) ^b	59.00(\pm 8.10) ^b

Groups: G1: Inhalation control; G2: Oral control; G3: Low inhalation concentration; G4: Low oral concentration; G5: Medium inhalation concentration; G6: Medium oral concentration; G7: High inhalation concentration; G8: High oral concentration. F: Female; M: Male. AST: Aspartate aminotransferase; ALT: Alanine aminotransferase. Lowercase letters are used to compare groups simultaneously and within the same column. Distinct letters indicate a significance level of $p < 0.05$, whereby $a \neq b$, $b \neq a$, c ; $c \neq a$, b

Table 3: Mean (\pm standard deviation) of the number of NORs (nucleoli-organizing regions) in hepatocytes per study group, regardless of the gender of the animals (n = 79)

Groups	Number of NORs	Groups	Number of NORs
G1	202.7(\pm 15.24) ^{Aa}	G2	234.0(\pm 7.82) ^{Aa}
G3	285.1(\pm 16.36) ^{Ab}	G4	380.1(\pm 34.10) ^{Bb}
G5	507.1(\pm 41.12) ^{Ac}	G6	642.4(\pm 35.09) ^{Bc}
G7	911.6(\pm 69.05) ^{Ad}	G8	1159.0(\pm 58.01) ^{Bd}

Groups: G1: Inhalation control; G2: Oral control; G3: Low inhalation concentration; G4: Low oral concentration; G5: Medium inhalation concentration; G6: Medium oral concentration; G7: High inhalation concentration; G8: High oral concentration. Capital letters compare groups on the same line. Lowercase letters are used to compare groups simultaneously and within the same column. Distinct letters indicate a significance level of $p < 0.05$, whereby $A \neq B$; $a \neq b$, c , d ; $b \neq a$, c , d ; $c \neq a$, b , d ; $d \neq a$, b , c

Table 4: Number of NORs (nucleoli-organizing regions) (mean \pm standard deviation) in the renal tubules per study group, regardless of the gender of the animals (n = 79)

Groups	Number of NORs	Groups	Number of NORs
G1	145.5(\pm 20.98) ^{Aa}	G2	143.1(\pm 13.73) ^{Aa}
G3	187.7(\pm 26.03) ^{Ab}	G4	216.3(\pm 13.14) ^{Ab}
G5	227.4(\pm 16.67) ^{Ac}	G6	196.5(\pm 6.55) ^{Ac}
G7	235.2(\pm 8.40) ^{Ac}	G8	255.6(\pm 16.65) ^{Ad}

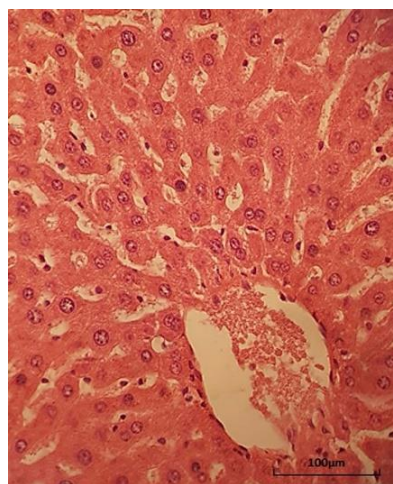
Groups: G1: Inhalation control; G2: Oral control; G3: Low inhalation concentration; G4: Low oral concentration; G5: Medium inhalation concentration; G6: Medium oral concentration; G7: High inhalation concentration; G8: High oral concentration. Capital letters compare groups on the same line. Lowercase letters are used to compare groups simultaneously and within the same column. Distinct letters indicate a significance level of $p < 0.05$, whereby $A \neq B$; $a \neq b$, c , d ; $b \neq a$, c , d ; $c \neq a$, b , d ; $d \neq a$, b , c

Most of the animals exposed to GBH presented tubular alterations, predominantly of the hydropic degeneration type, while control group animals did not show alterations ($p = 0.00001$). The highest incidence of tubular necrosis occurred in animals in the G8 group (30% of cases) ($p = 0.0162$) (Figs. 6-7). No statistically significant difference was observed between animal genders about the incidence of tubular alteration ($p = 0.4850$).

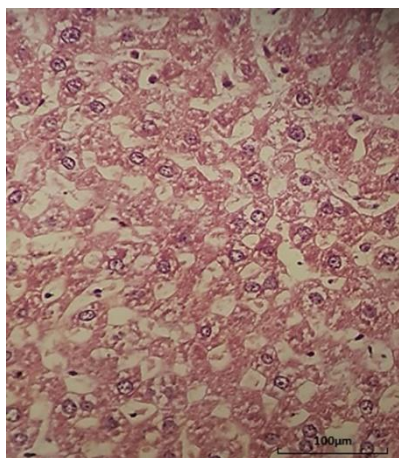
The medium and high GBH concentrations groups had the highest NOR numbers ($p = 0.001$). There were no differences in the NOR numbers between genders ($p = 0.4407$) and routes of exposure ($p = 0.8272$) (Table 4).

Pancreas and Spleen

There were no changes in the pancreas and spleen of all tested animals.

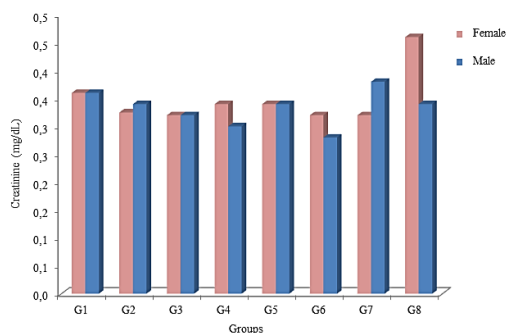


(a)

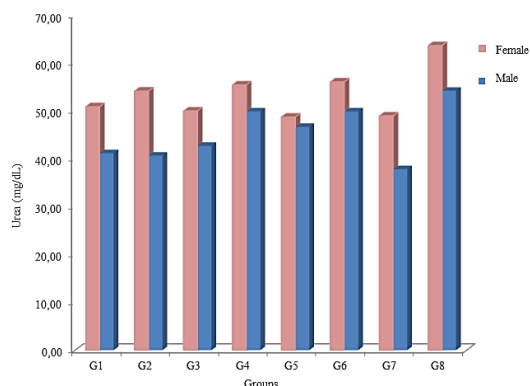


(b)

Fig. 4: Photomicroscopy of the liver; A-Normal hepatic parenchyma (male animal of the G1 group); B-Liver steatosis. Note microvacuolization of the hepatocyte cytoplasm (male animal of the G5 group). Haematoxylin-eosin, 400× magnification (100 µm scale bar)



(a)



(b)

Fig. 5: Mean serum concentrations in the tested groups and male and female animals (n = 79); A-Creatinine (mg/dL); B-Urea (mg/dL). Groups: G1: Inhalation control; G2: Oral control; G3: Low inhalation concentration; G4: Low oral concentration; G5: Medium inhalation concentration; G6: Medium oral concentration; G7: High inhalation concentration; G8: High oral concentration

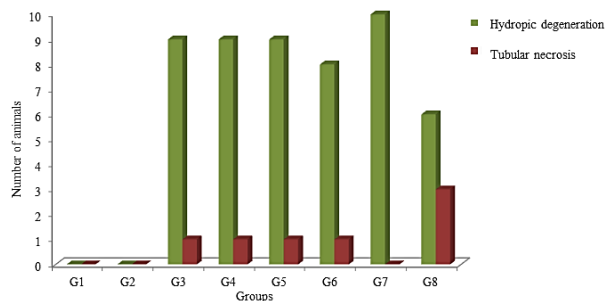
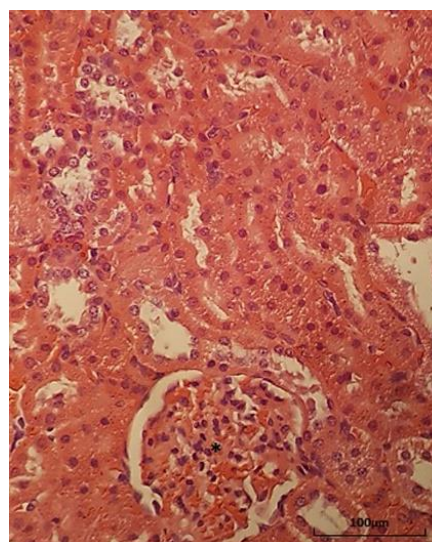
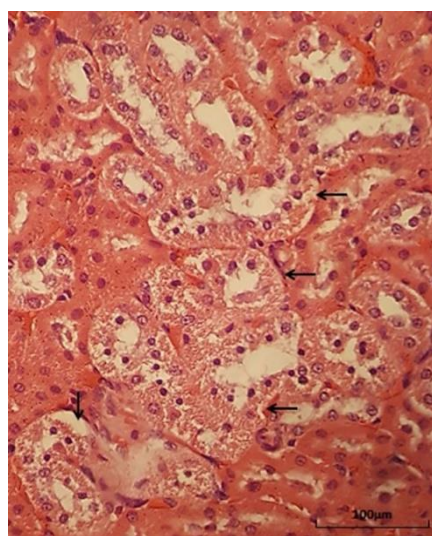


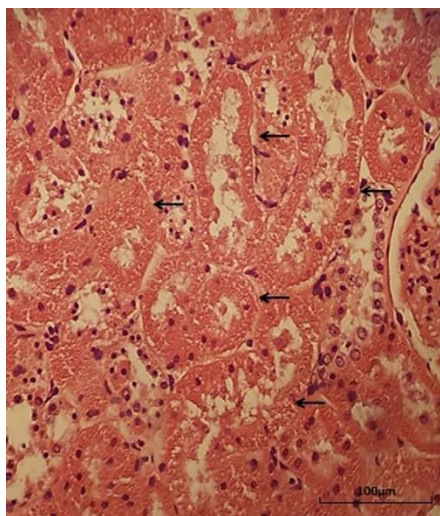
Fig. 6: Number of animals with tubular changes (hydropic degeneration and tubular necrosis) in the groups regardless of gender (n = 79). Groups: G1: Inhalation control; G2: Oral control; G3: Low inhalation concentration; G4: Low oral concentration; G5: Medium inhalation concentration; G6: Medium oral concentration; G7: High inhalation concentration; G8: High oral concentration



(a)



(b)



(c)

Fig. 7: Photomicroscopy of the kidney. A-Renal parenchyma with normal tubules and glomeruli (*) (female animal of group G1). B-Renal tubular hydropic degeneration. Note the vacuolated cytoplasm of the renal tubules (arrows) (female animal of the G3 group). C-Acute tubular necrosis. Note the absence of the nuclei in some tubules and nuclear fragmentation in other tubules (arrows) (female animal of the G4 group). Haematoxylin-eosin, 400× magnification (100 µm scale bar)

Discussion

We observed an increase in the AST and ALT levels in animals exposed to GBH, mainly in females and in high-concentration orally exposed animals; additionally, the level of steatosis was highest in all animals subjected to medium and high GBH concentrations. Females exposed to a high concentration orally showed the highest levels of urea and a higher prevalence of renal tubular necrosis. The numbers of NORs in the liver and kidney were higher in animals exposed to medium and high GBH concentrations and the numbers of NORs were higher in the liver in the groups exposed orally.

A study that used Sprague-Dawley rats orally treated with various doses of glyphosate demonstrated a decrease in weight, weight gain, and average daily weight gain after 35 days of exposure (Tang *et al.*, 2017). The weight or intake of feed was similar in the groups exposed and unexposed to GBH in this study. Our study used lower doses of GBH compared to that in the previous studies and did not use gavage (an unusual route of human exposure) to administer glyphosate thus possibly contributing to a lack of a reduction in weight or ingestion of feed.

A study of fish exposed to glyphosate (sublethal doses in water) for one or two days in water demonstrated a moderate degeneration of hepatocytes and hepatic fibrosis (Topal *et al.*, 2015). Another study with rats orally exposed to glyphosate for 35 days demonstrated an increase in the AST and ALT levels, apoptosis of some hepatocytes, focal

necrosis, and infiltration of mononuclear cells; these changes were more evident in animals submitted to higher dosages of glyphosate and were associated with an increase in the interleukin (IL)-1b level, a proinflammatory marker (Tang *et al.*, 2017). Another study with rats exposed to glyphosate in drinking water showed nucleolar ruptures in hepatocytes and a significant increase in the cell and cytoplasmic area according to the data from electron microscopy (Mesnage *et al.*, 2015a). A report on a case of the suicide attempt of a young woman by ingestion of 500 mL of a concentrated formulation of Roundup (a GBH) demonstrated considerable congestion of liver sinuses and mild microvesicular and macrovesicular steatosis in the centrilobular region (Sribanditmongkol *et al.*, 2012). In our study, serum AST concentrations were higher in animals of low and medium inhalation concentrations and high oral concentration groups and ALT concentrations were higher in the medium and high GBH concentrations groups. Hepatic mononuclear inflammatory infiltration has been described in some studies (Tang *et al.*, 2017); however, we observed a similar pattern only in three animals exposed to GBH possibly because we used lower concentrations compared to that used in the previous studies, which may also justify a lack of tissue or vascular necrosis.

We did not observe inflammation in most exposed animals; Nonetheless, a gradual rise in NOR numbers was evident, with a more significant increase observed in the groups exposed to higher GBH concentrations and in those subjected to oral exposure. NORs indicate cell proliferation (Pegoraro *et al.*, 2021). These data indicate hepatocyte destruction and apparent regeneration in the liver of exposed animals regardless of inflammatory stimulus. These events may explain an ALT and AST levels increase that was especially pronounced in the higher concentrations of GBH groups.

In this study, microvesicular hepatic steatosis (associated with exposure to most chemical agents) was identified in the majority of animals exposed to low inhalation concentration and medium and high oral and inhalation concentrations. Steatosis is the storage of triglycerides within hepatocytes due to changes in lipid metabolism (Hammer *et al.*, 2010). Lipotoxic conditions, oxidative stress and metabolic alterations linked to hepatotoxicity markers were detected in a study with exposure of rats to GBH (Mesnage *et al.*, 2017). Hepatic steatosis detected in this study and results of another study, which described an increase in the serum triglyceride levels in animals exposed to glyphosate (Mesnage *et al.*, 2015a), indicate that this GBH can alter hepatic lipid metabolism. Additionally, our study corroborates the data of other studies, which demonstrated that higher doses/concentrations of GBH, even used as described in the package insert, cause higher liver damage.

Pesticides have been proposed as potential contributors to multifactorial chronic kidney disease, mainly in association with other factors like fluoride exposure, dehydration, and malnutrition (Wimalawansa, 2016); moreover, glyphosate has been linked to agricultural nephropathy in certain farming regions across the globe (Jayasumana *et al.*, 2015). Studies in ATS exposed to glyphosate exhibited alterations in various biochemical and urinary parameters, including loss of ions and decreased urinary creatinine, which suggests impaired renal function (Mesnage *et al.*, 2015a). An increased quantity of apoptotic and necrotic cells, primarily within the tubular epithelium, was demonstrated. Tubular necrosis and glomerular toxicity were found to be correlated with elevated creatinine levels and exposure to higher doses of glyphosate (Wunnapuk *et al.*, 2014; Tang *et al.*, 2017). A report on a case of acute intoxication by a high dose of GBH in a young woman detected vascular congestion and proteinaceous cylinders in the glomerular tufts and in the light regions of the tubules in the kidney (Sribanditmongkol *et al.*, 2012). In this study, the serum concentrations of creatinine and urea were higher in the high oral GBH concentration group and tubular alteration was detected only in the exposed groups. The counts of NORs were elevated in the groups exposed to medium and high concentrations corresponding to a required increase in reepithelialisation of the tubules in these animals. No significant disparities in NOR numbers between the exposure routes (oral and inhalation) were observed; nonetheless, NOR counts were greater in the high oral concentration group and this group had a higher incidence of tubular necrosis (30% of the animals) and higher serum creatinine and urea levels. Our data confirm possible functional and morphological kidney damage induced by exposure to GBH even at the concentrations described in the product labeling information and indicate that high concentrations are more harmful to the kidney.

A study in Sprague-Dawley rats subjected to exposure to glyphosate in water detected higher acute liver and kidney damage in males versus females and a greater occurrence of premature death in the animals (Mesnage *et al.*, 2015a). AST and ALT are important markers of liver damage and Genetic factors have a significant impact on the gender-specific differences in the blood levels of these markers (Van Beek *et al.*, 2013). Studies in animals (Brkić *et al.*, 2015) and humans (Attanasio, 2019) have demonstrated that females have higher levels of ALT and AST upon exposure to hepatotoxic agents. The levels of urea and creatinine can also be influenced by gender in humans (Tzamaloukas *et al.*, 1998). A study on the exposure of rats to cisplatin demonstrated that females had higher levels of urea and creatinine than males (Jilanchi *et al.*, 2018). Like other studies, higher levels of AST, ALT, and urea were

observed in females exposed to GBH than those in males in this study; however, no gender-based distinctions were observed in the histological parameters (structural damage and NOR numbers). Our data indicate that females manifest higher levels of functional damage upon exposure to GBH; however, this effect does not correspond to greater structural damage.

Histological changes in the spleen were not detected in this study. An earlier investigation on chronic exposure to herbicide 2,4-dichlorophenoxyacetic acid (2,4-D) used exposure routes like those used in our study, also did not detect alterations in the spleen (Bonfim *et al.*, 2020). In animals exposed to GBH, the absence of liver fibrosis or cirrhosis that causes portal hypertension, which may result in splenic congestion (red pulp hyperplasia) and inflammation in the evaluated organs, which may result in white pulp hyperplasia, thus justifying apparent lack of changes in the spleen.

Some studies have shown an association between exposure to various classes of pesticides and type II diabetes (organophosphates, organochlorines, carbamates, and insecticides) in humans (Everett and Matheson, 2010; Evangelou *et al.*, 2016; Juntarawijit and Juntarawijit, 2018) and this relationship is more prominent in individuals with obesity (Park *et al.*, 2019). Rats chronically exposed for six months to 2,4-D manifested atrophy of the islets of Langerhans (Bonfim *et al.*, 2020). In this, changes in the pancreas were not detected in animals exposed to GBH. Apparently, the pancreas is not the target organ of GBH used at the concentrations described in the product labeling information; alternatively, the subchronic exposure used (75 days) is insufficient to induce the changes. Studies involving prolonged exposure to GBH may determine whether the pancreas is the target organ for this pesticide.

Several studies have demonstrated that exposure to glyphosate results in oxidative stress in various organs and tissues, including the liver and kidneys (Tang *et al.*, 2017). The generation of reactive oxygen species linked to glyphosate exposure could potentially explain the alterations detected in the liver and kidney in this study and other studies. Future investigations that contrast the results of oxidative stress with tissue morphological alterations in the liver and kidney through exposure to different concentrations of GBH could offer clearer insight into the genesis of lesions in these organs and establish safer exposure limits.

Also, investigations that assess the individual glyphosate internal dosage for each animal, beyond the concentration of glyphosate present in the contaminated feed over an extended period that typifies chronic exposure (repeated or continuous exposures to low pesticide doses for a period exceeding 3 months), could offer a more precise understanding of the dose-response relationship and the enduring consequences that this GBH

may induce. Likewise, other common routes of exposure to GBHs (e.g., dermal and Trans placental) need to be evaluated to broaden the understanding of the hepatotoxic and nephrotoxic effects caused by this herbicide.

GBH is defined as a mixture of the active component glyphosate with other substances called "inert ingredients", which improve their solubility, absorption, and stability in plants. These GBH formulations may vary according to each manufacturer or country where it was produced. The "inert ingredients" are a trade secret and can potentiate the toxic effect of glyphosate. Also, the active component glyphosate can be marketed in the form of different salts that have different toxic effects (Mesnage *et al.*, 2019). Thus, it is essential to highlight that our data refer to a specific formulation of glyphosate di-ammonium salt.

Conclusion

Our study incorporates the following new data into the literature on exposure to GBHs: Even 75-day (sub-chronic) exposure to GBH (by inhalation or orally) can cause liver and kidney damage; high concentrations of GBH, mainly orally, causes substantial liver and kidney damage (functional and morphological); females manifest more pronounced hepatic and renal biochemical changes than males; and tissue damage was detected even when utilizing the concentrations specified in product labeling information provided by the manufacturer.

Acknowledgment

To Ana Vanuire Rombi from the laboratory of clinical analysis at the veterinary hospital of Universidade do Oeste Paulista (UNOESTE) for performing the biochemical analyses. And to the technicians from the laboratory of surgical pathology and cytopathology at UNOESTE (Carlos Alexandre Santana de Oliveira, Mariana Fonseca Motta Borges, and Talita Rizo Pereira) for processing histological samples.

Funding Information

This study was funded through research grants provided by Universidade do Oeste Paulista (UNOESTE).

Author's Contributions

Fernanda de Maria Serra: Participated in all experiments, coordinated the data-analysis and contributed to the written of the manuscript.

Letícia Rocha Magalhães, Beatriz Bertholace Magalhães Silva, Emmanuela Beatriz Vantini Barreiro, Isabela Benes Franco and Isabela Melo Nogueira: Participated in all experiments.

Liliane Aparecida Tanus Benatti: Designed the research planed and organized the study.

Rogério Giuffrida: Designed the research planed.

Gisele Alborghetti Nai: Designed the research planed, organized the study and contributed to the written of the manuscript.

Ethics

This article is original and contains unpublished material. The corresponding author confirms that all authors have read and approved the manuscript and that there are no ethical issues.

Conflict of Interest

The authors have declared no conflict of interest.

References

- Attanasio, R. (2019). Sex differences in the association between perfluoroalkyl acids and liver function in US adolescents: Analyses of NHANES 2013-2016. *Environmental Pollution*, 254, 113061. <https://doi.org/10.1016/j.envpol.2019.113061>
- Benbrook, C. M. (2016). Trends in glyphosate herbicide use in the United States and globally. *Environmental Sciences Europe*, 28(1), 1-15. <https://doi.org/10.1186/s12302-016-0070-0>
- BfR. (2014). The BfR has finalised its draft report for the re-evaluation of glyphosate. *German Federal Agency*. http://www.bfr.bund.de/en/the_bfr_has_finalised_its_draft_report_for_the_re_evaluation_of_glyphosate-188632.html
- Bonfim, D. J. P., Magalhães, L. R., Chagas, P. H. N., Serra, F. D. M., Benatti, L. A. T., & Nai, G. A. (2020). Hepatic, renal and pancreatic damage associated with chronic exposure to oral and inhaled 2,4-dichlorophenoxy acetic acid (2,4-d): An environmental exposure model in rats. *Comparative Clinical Pathology*, 29(5), 1001-1010. <https://doi.org/10.1007/s00580-020-03150-8>
- Brkić, D., Szakonyne-Pasics, I., Gašić, S., Teodorović, I., Rašković, B., Brkić, N., & Nešković, N. (2015). Subacute and subchronic toxicity of Avalon® mixture (bentazone + dicamba) to rats. *Environmental Toxicology and Pharmacology*, 39(3), 1057-1066. <https://doi.org/10.1016/j.etap.2015.03.004>
- Deugnier, Y., & Turlin, B. (2007). Pathology of hepatic iron overload. *World Journal of Gastroenterology: WJG*, 13(35), 4755. <https://doi.org/10.3748/wjg.v13.i35.4755>
- Evangelou, E., Ntritsos, G., Chondrogiorgi, M., Kavvoura, F. K., Hernández, A. F., Ntzani, E. E., & Tzoulaki, I. (2016). Exposure to pesticides and diabetes: A systematic review and meta-analysis. *Environment International*, 91, 60-68. <https://doi.org/10.1016/j.envint.2016.02.013>

- Everett, C. J., & Matheson, E. M. (2010). Biomarkers of pesticide exposure and diabetes in the 1999-2004 national health and nutrition examination survey. *Environment International*, 36(4), 398-401. <https://doi.org/10.1016/j.envint.2010.02.010>
- Hammer, G. D., McPhee, S. J., & Education, M. H. (Eds.). (2010). Pathophysiology of Disease: An Introduction to Clinical Medicine 8E. *Pathophysiology*. <https://apps.apple.com/jm/app/pathophysiology-of-disease-an-introduction-to/id879056609>
- Jayasumana, C., Gunatilake, S., & Siribaddana, S. (2015). Simultaneous exposure to multiple heavy metals and glyphosate may contribute to Sri Lankan agricultural nephropathy. *BMC Nephrology*, 16(1), 1-8. <https://doi.org/10.1186/s12882-015-0109-2>
- Jilanchi, S., Talebi, A., & Nematbakhsh, M. (2018). Cisplatin alters sodium excretion and renal clearance in rats: gender and drug dose related. *Advanced Biomedical Research*, 7. https://doi.org/10.4103/abr.abr_124_17
- Juntarawijit, C., & Juntarawijit, Y. (2018). Association between diabetes and pesticides: A case-control study among Thai farmers. *Environmental Health and Preventive Medicine*, 23(1), 1-10. <https://doi.org/10.1186/s12199-018-0692-5>
- Krüger, M., Schrödl, W., Neuhaus, J., & Shehata, A. A. (2013). Field investigations of glyphosate in urine of Danish dairy cows. *J Environ Anal Toxicol*, 3(5), 100186. <https://doi.org/10.4172/2161-0525.1000186>
- Landrigan, P. J., & Belpoggi, F. (2018). The need for independent research on the health effects of glyphosate-based herbicides. *Environmental Health*, 17(1), 1-4. <https://doi.org/10.1186/s12940-018-0392-z>
- Mello, F. A., Quinallia, G., Marion, A. L., Jorge, F. C., Marinelli, L. M., Salge, A. K. M., ... & Rossi e Silva, R. C. (2018). Evaluation of the nasal cavity mice submitted to the inhalation exposure to the herbicide 2, 4-dichlorophenoxyacetic acid. *Medicina (Ribeirão Preto, Online)*, 51(4), 247-253. <https://doi.org/10.11606/issn.2176-7262.v51i4p247-253>
- Mesnager, R., Arno, M., Costanzo, M., Malatesta, M., Séralini, G. E., & Antoniou, M. N. (2015a). Transcriptome profile analysis reflects rat liver and kidney damage following chronic ultra-low dose Roundup exposure. *Environmental Health*, 14, 1-14. <https://doi.org/10.1186/s12940-015-0056-1>
- Mesnager, R., Defarge, N., De Vendômois, J. S., & Séralini, G. E. (2015b). Potential toxic effects of glyphosate and its commercial formulations below regulatory limits. *Food and Chemical Toxicology*, 84, 133-153. <https://doi.org/10.1016/j.fct.2015.08.012>
- Mesnager, R., Renney, G., Séralini, G. E., Ward, M., & Antoniou, M. N. (2017). Multiomics reveal non-alcoholic fatty liver disease in rats following chronic exposure to an ultra-low dose of Roundup herbicide. *Scientific Reports*, 7(1), 39328. <https://doi.org/10.1038/srep39328>
- Mesnager, R., Benbrook, C., & Antoniou, M. N. (2019). Insight into the confusion over surfactant co-formulants in glyphosate-based herbicides. *Food and Chemical Toxicology*, 128, 137-145. <https://doi.org/10.1016/j.fct.2019.03.053>
- Olorunsogo, O. O., Bababunmi, E. A., & Bassir, O. (1979). Effect of glyphosate on rat liver mitochondria in vivo. *Bulletin of Environmental Contamination and Toxicology*, 22, 357-364. <https://doi.org/10.1007/BF02026955>
- Paiva, F. D., Maffili, V. V., & Santos, A. C. S. (2005). Curso de manipulação de animais de laboratório. *Fundação Osvaldo Cruz. Centro De Pesquisas Gonçalo Muniz*. http://www.bioteriocentral.ufc.br/arquivos/apostilha_manipulacao.pdf
- Park, S., Kim, S. K., Kim, J. Y., Lee, K., Choi, J. R., Chang, S. J., ... & Koh, S. B. (2019). Exposure to pesticides and the prevalence of diabetes in a rural population in Korea. *Neurotoxicology*, 70, 12-18. <https://doi.org/10.1016/j.neuro.2018.10.007>
- Pegoraro, C. M. R., Nai, G. A., Garcia, L. A., Serra, F. D. M., Alves, J. A., Chagas, P. H. N., ... & Zocoler, M. A. (2021). Protective effects of Bidens pilosa on hepatotoxicity and nephrotoxicity induced by carbon tetrachloride in rats. *Drug and chemical Toxicology*, 44(1), 64-74. <https://doi.org/10.1080/01480545.2018.1526182>
- Pingali, P. L. (2012). Green revolution: Impacts, limits and the path ahead. *Proceedings of The National Academy of Sciences*, 109(31), 12302-12308. <https://doi.org/10.1073/pnas.1107959108>
- Ploton, D., Menager, M., Jeannesson, P., Himber, G., Pigeon, F., & Adnet, J. J. (1986). Improvement in the staining and in the visualization of the argyrophilic proteins of the nucleolar organizer region at the optical level. *The Histochemical Journal*, 18, 5-14. <https://doi.org/10.1007/BF01676192>
- Sribanditmongkol, P., Jutavijittum, P., Pongraveevongsa, P., Wunnapak, K., & Durongkadech, P. (2012). Pathological and toxicological findings in glyphosate-surfactant herbicide fatality: A case report. *The American Journal of Forensic Medicine and Pathology*, 33(3), 234-237. <https://doi.org/10.1097/PAF.0b013e31824b936c>
- Tang, J., Hu, P., Li, Y., Win-Shwe, T. T., & Li, C. (2017). Ion imbalance is involved in the mechanisms of liver oxidative damage in rats exposed to glyphosate. *Frontiers in Physiology*, 8, 1083. <https://doi.org/10.3389/fphys.2017.01083>

- Team, R. D. C. (2023). R: A language and environment for statistical computing.
<https://cir.nii.ac.jp/crid/1370294721063650048>
- Topal, A., Atamanalp, M., Uçar, A., Oruç, E., Kocaman, E. M., Sulukan, E., ... & Ceyhun, S. B. (2015). Effects of glyphosate on juvenile rainbow trout (*Oncorhynchus mykiss*): Transcriptional and enzymatic analyses of antioxidant defence system, histopathological liver damage and swimming performance. *Ecotoxicology and Environmental Safety*, 111, 206-214.
<https://doi.org/10.1016/j.ecoenv.2014.09.027>
- Tzamaloukas, A. H., Malhotra, D., & Murata, G. H. (1998). Gender, degree of obesity and discrepancy between urea and creatinine clearance in peritoneal dialysis. *Journal of the American Society of Nephrology*, 9(3), 497-499.
<https://doi.org/10.1681/ASN.V93497>
- Van Beek, J. H., de Moor, M. H., de Geus, E. J., Lubke, G. H., Vink, J. M., Willemsen, G., & Boomsma, D. I. (2013). The genetic architecture of liver enzyme levels: GGT, ALT and AST. *Behavior Genetics*, 43, 329-339.
<https://doi.org/10.1007/s10519-013-9593-y>
- Wimalawansa, S. J. (2016). The role of ions, heavy metals, fluoride and agrochemicals: Critical evaluation of potential aetiological factors of chronic kidney disease of multifactorial origin (CKDmfo/CKDu) and recommendations for its eradication. *Environmental Geochemistry and Health*, 38(3), 639-678.
<https://doi.org/10.1007/s10653-015-9768-y>
- Wunnapuk, K., Gobe, G., Endre, Z., Peake, P., Grice, J. E., Roberts, M. S., ... & Liu, X. (2014). Use of a glyphosate-based herbicide induced nephrotoxicity model to investigate a panel of kidney injury biomarkers. *Toxicology Letters*, 225(1), 192-200.
<https://doi.org/10.1016/j.toxlet.2013.12.009>